Treatment of meniscal lesions in the knee

Epidemiological, clinical and experimental aspects

Adam Hede

From the Departments of Orthopedic Surgery, Rigshospitalet and Gentofte Hospital, University of Copenhagen, Denmark

This thesis is based upon the following publications:

1) Hede A, Jensen D B, Blyme P, Sonne-Holm S. Epidemiology of meniscal lesions in the knee. Acta Orthop Scand 1990b; 61(5): 435-437.

2) Hede A, Hejgaard N, Larsen E. Partial or total open meniscectomy? A prospective, randomized study. Internat Orthop 1986; 10: 105-108.

3) Hede A, Larsen E, Sandberg H. Partial versus total meniscectomy. A prospective, randomised study with long-term follow-up. J Bone Joint Surg 1992a; 74-B: 118-121.

4) Hede A, Larsen E, Sandberg H. The long term outcome of open total and partial meniscectomy related to the quantity and site of the meniscus removed. Internat Orthop 1992b; 16: 122-125.

5) Hede A, Hempel-Poulsen S, Jensen JS. Symptoms and level of sports activity in patients awaiting arthroscopy for meniscal lesions of the knee. J Bone Joint Surg 1990a; 72-A: 550-552.

6) Hede A, Svalastoga E, Reimann I. Repair of three-month-old experimental meniscal lesions in rabbits. Clin Orthop 1991a; 266: 238-243.

7) Hede A, Svalastoga E, Reimann I. Articular cartilage changes following meniscal lesions. Repair and meniscectomy studied in the rabbit knee. Acta Orthop Scand 1991b; 62(4): 319-322.

8) Hede A, Madsen J, Svalastoga E, Bülow J. Radionuclide uptake in experimentally induced meniscal lesions in rabbit knees. Acta Vet Scand 1989; 30: 229-230.

Preface

The clinical work included in this thesis was begun during my appointment to the Department of Orthopaedic Surgery, Gentofte County Hospital where Niels Hejgaard, M. D. was an outstanding and inspiring initiator before dying very untimely. I am deeply indebted to the former head of this department the late Preben Thestrup Andersen M. D., Ph. D., who constantly stimulated and encouraged my interest in knee surgery. During the later part of the study the present chief of that department Jens Kristian Gøtrik M. D. provided excellent working conditions and made it possible for me to use the radiological equipment at the Department of Radiology. I am greatly indebted to medical secretaries Sanne Helmer Nielsen, Anne-Lise Bovbjerg and Ulla Hammer-Jacobsen who with great patience kept the files and summoned patients.

The experimental study was carried out at the Institute for Experimental Research in Surgery, University of Copenhagen, where Henning Peter Olesen D. V. M. and his staff offered a splendid environment for experimental research. Tissues were prepared and examined at the Calcified Tissue Research Laboratory of the Department of Orthopaedic Surgery, Rigshospitalet. I am indebted to Carl Christian Arnoldi M. D., Ph. D. and to Bjarne Lund M. D., Ph. D. for their interest and support. Particular thanks are due to Karen-Elisabeth Sønderlev, histotechnician, for the hard work and conscionable methods of tissue processing.

I wish to thank my co-authors for excellent cooperation and Steen Bach Christensen M. D., Ph. D. and Søren Solgaard M. D. for constructive advice. Michael Davidsen M. Sc., Department of Data Processing in Medicine, Herlev County Hospital, performed most of the statistical analyses and took eager interest in analysis of the problems and results.

A great deal of the sporadic spare time was spent sailboat racing with Jens Henriksen M. Sc. Ashore he taught me the excessive capabilities of my computer software. I owe so much gratitude to Jörgen Lindholm M. D., Ph. D. for countless hours of stimulating discussions and for improving my English.

Financial support for the individual studies was granted by the Danish Sports Research Council. Financial aid for publication of this review was received from The Danish Medical Research Council and Winterthur-Borgen Insurance Company.

Table of Contents

1. Introduction

In 1803 William Hey in Leeds was the first to describe a dislocated meniscus as a cause of knee joint dysfunction. The first meniscal operation was performed at St. George's Hospital in London in 1866 by Bradhurst (Helfet 1974). The treatment was usually manipulation until Lister's work from 1867 on antiseptics prepared the way for surgical treatment. In 1883 Thomas Annandale performed the first meniscal repair by relocating and suturing a detached anterior horn (Annandale 1885).

Excision of the fibrocartilage soon became the preferred treatment of meniscal lesions. Many authors were enthusiastic about this procedure, reporting excellent functional results rarely followed by degenerative joint changes (Hamilton and Finklestein 1943, Wynn-Parry et al. 1958, Perey 1962). It was emphasized that excision of the total meniscus was important (McMurray 1941) and that it was particularly hazardous to leave a posterior horn behind (Tapper and Hoover 1969).

Data slowly accumulated in the 1970s to a point where the pendulum started to swing towards a more conservative approach (Goodfellow 1980). Due to persistent symptoms after total meniscectomy, partial resection with excision of the damaged portion only has increasingly been employed and is considered superior to total meniscectomy as it causes less degeneration of the knee joint (Hamberg et al. 1984, Odgaard et al. 1989). This shift in surgical procedure was based on studies that were retrospective cross sectional investigations and based on selected patients providing no data on changes in symptoms, clinical and radiographic findings after surgery (Tapper and Hoover 1969, Johnson et al. 1974). Additionally, the investigations suffered from the fact that the type of meniscal lesion and preferences of the surgeon determined which surgical procedure was to be performed (Franke 1966, McGinty et al. 1977).

Today, meniscal surgery is one of the most common orthopedic procedures. An association has repeatedly been reported between meniscal disease respectively removal of meniscal tissue and cartilage degeneration (Tapper and Hoover 1969, Johnson et al. 1974).

Little is known about the occurrence and treatment of meniscal lesions in the general population. Men seem to suffer meniscal lesions more often than women but this information is based on calculations of patients operated on without considering the background population (Saugmann-Jensen 1963, Whipple et al. 1984).

It has never been established how much fibrocartilage should be removed when performing partial meniscectomy. Furthermore, little is known of whether all categories of meniscal lesions benefit from partial meniscectomy when compared to total excision.

The clinical diagnosis of meniscal lesions is difficult even in experienced hands (Hede and Hejgaard 1981, Anderson and Lipscomb 1986). In some patients symptoms suggesting meniscal disorder are highly disabling and may change during the period of time before establishing diagnosis and undertaking treatment (Shakespeare and Rigby 1983). Thus, delay in diagnosing might affect the number of patients examined and treated for a meniscal lesion. This would bear on the economic resources necessary for treating the disease.

Meniscal repair has increasingly been advocated as an alternative to meniscectomy with the purpose of causing minimal interference with the normal biomechanics of the joint. It has been performed in both recent and old lesions in the vascularized peripheral third of the meniscus (Hamberg et al. 1983b). In contrary, tears in the central and avascular two thirds of the meniscus do not heal even after suturing (Arnoczky and Warren 1983).

In experimental models healing of recent defects in the central area have been attained. Other studies have assessed the effect of displaced

meniscal lesions and meniscectomy on the joint cartilage. Considering the delay in treatment of most meniscal lesions it remains to be investigated whether old lesions in the avascular part of the meniscus can be repaired. It is also unclear which influence repair of them has on the joint cartilage and whether this procedure is preferable to meniscectomy and no treatment in terms of preserving joint cartilage.

On this background it was relevant to

- Study the epidemiology of surgically treated meniscal lesions.
- Assess the onset of symptoms in relation to trauma and study the association between trauma and occurrence of different lesions, especially differences between men and women.
- Compare the clinical, functional and radiological outcome after partial and total meniscectomy in a group of patients randomized to one of the surgical procedures and to compare the short and long term results defining risk factors for the eventual outcome.
- Determine the result of partial and total meniscectomy in treatment of different meniscal lesions in relation to the extent of the former procedure.
- Investigate the spontaneous course of symptoms and physical performance in patients awaiting treatment of a presumed meniscal lesion.
- Investigate the influence of a well defined and undisplaceable meniscal lesion on the hyaline cartilage and adjacent bone.
- Develop an experimental model of repairing old lesions in the avascular part of the meniscus and to use this model in the study on joint cartilage comparing meniscectomy, repair and no treatment.

2. Epidemiology

There is no generally accepted classification of meniscal lesions. They can be classified according to their shape, position in relation to the anterior or posterior horn of the meniscus and to whether they can be or actually are displaced. Furthermore, lesions can be graded according to their etiology as following a direct trauma, as degenerative lesions or as lesions following ligamentary knee instability.

Peripheral detachments, bucket-handle lesions and transverse tears classified as either parrot-beak or radial tears are all vertical lesions often seen following injuries while cleavage tears including flap tears are located horizontally and assumed to rise from areas of degenerated fibrocartilage (Smillie 1977, Reikerås 1989). The lesions illustrated in Figure 2-1 are included in most morphological classifications (Wynn-Parry et al. 1958, Lidge 1979) but in clinical practice combinations and transitional forms occur. Dandy (1990) has in detail described the anatomy of 1,000 symptomatic lesions.

Recently the meniscal structure has been clarified. In the peripheral part of the fibrocartilage the bundles of collagen fibers are densely packed with a circumferential pattern (Bullough et al. 1970, Beaupré et al. 1986) (Figure 2-2). After leaving the periphery the fibers arch through the middle zone with a nearly radial direction and decreasing density in the central part (Wagner 1976). Meniscal lesions tend to occur parallel to the collagen bundles (Bullough et al. 1970).

The clinical diagnosis of meniscal pathology appears to be erroneous in about a third of the cases (Hede and Hejgaard 1981, Anderson and Lipscomb 1986). Hede and Hejgaard (1981) demonstrated that joint line tenderness was the most predictive clinical finding, as confirmed by other authors (Anderson and Lipscomb 1986, Abdon et al. 1990a).

Arthrography has been used in settling the indication for explorative arthrotomy (Gillies and Seligson 1979, Schmidt 1982, Daniel et al. 1982, Roper and Levack 1986). The diagnostic accuracy has varied between 84 and 98 percent (Gillies and Seligson 1979, Ireland et al. 1980), being slightly higher in medial than in lateral lesions (Nicholas et al. 1970, Schmidt 1982). Roper and Levack (1986) found in only 72 percent a complete correlation between the preoperative arthrographic diagnosis and the definite surgical diagnosis obtained at open surgery.

Arthroscopy and double-contrast arthrography were equally accurate in the series of Ireland et al. (1980). Theoretically, the diagnostic accuracy can be enhanced by combining arthroscopic and radiographic techniques (Levinsohn and Baker 1980).

Today the arthroscopic examination is regarded as the key to recognizing meniscal pathology. It is superior to direct inspection during explorative arthrotomy (DeHaven and Collins 1975) since incorrect arthroscopic interpretation occurs only in a few percent (Dandy and Jackson 1975b, Lysholm et al. 1981). Arthroscopy has also replaced arthrography as the diagnostic method of choice, since the diagnostic and therapeutic procedures can be combined.

In recent years non-invasive methods as computed tomography and magnetic resonance imaging have proved valuable for the detection and description of meniscal tears (Passariello et al. 1985, Raunest et al. 1991). Further refinement may make non-invasive procedures preferable to arthroscopic examination.

Little is known about the occurrence and treatment of meniscal lesions in the general population though meniscal surgery is both a frequently performed and resource exacting procedure.

Studies on meniscal lesions in adults have till now been based on selected patients without a proper background population necessary for

epidemiologic assessments. The age of the patients appears to have increased during the last decades: Smillie (1967) found in 6,500 meniscectomies from 1940 through 1965 that the mean age rose from 27.6 to 39.8 years. However, this estimate might be biased as patients were recruited during war time and hence might include a large number of soldiers.

Meniscal lesions are frequently related to a trauma which has been taken to explain that they occur more frequently in men than in women (Barfod and Bierring 1956, Saugmann-Jensen 1963, Johnson et al. 1974, Dandy 1990). The ratio between men and women has varied but has always been presented without correlation to the background population.

Own Investigations

Methods

A total of 1,215 persons living in Copenhagen County, with approximately 620,000 inhabitants during 1982 through 1984, were treated during this period for a meniscal lesion at one of the three hospitals in the county performing orthopedic surgery. The mean age of the 812 men and 403 women was 36 (range 3-83) years.

To describe the total number of treated meniscal lesions rather than the number of different citizens, calculations and figures are presented without excluding patients who underwent more than one meniscus operation during the 3-year period.

From patient records information on whether a trauma was related to the onset of symptoms and type of lesion was obtained — a trauma being defined as a single episode of physical violence to the knee. Surgery was performed openly, and only 18 operations were preceded by a diagnostic arthroscopy. The meniscal lesions were classified according to Lidge (1979), with recording of other peroperative findings and type of operation performed. Men and women operated on were divided into 10-year age groups. The

population of Copenhagen County was stratified into similar groups according to information obtained from the Danish Central Bureau of Statistics.

The age and sex related incidences per 10,000 inhabitants **i** and the overall incidences for the 3-year period were calculated as

$$i_{age,\ sex} = \frac{10{,}000\ (\text{number of meniscotomies } 1982\text{-}1984)_{age,\ sex}}{0.5((inh1982+inh1983)+(inh1983+inh1984)+(inh1984+inh1985))_{age,\ sex}}$$

(inh is the number of inhabitants in Copenhagen County on January 1.)

A chi-square test was used in the calculation of the two-way relationships between the sex of the patients, trauma-associated onset of symptoms, and type of meniscal lesion. The three-way relationships between these three variables were analyzed with a chi-square test for conditional independence (Kreiner 1987).

Results

The overall annual incidence of meniscal lesions undergoing surgery was 9.0 and 4.2 per 10,000 for men and women. In men, the highest incidence was 17 in the 20-39 year-old age groups, gradually decreasing to 1 in patients above 70 years (Hede et al. 1990b) (Figure 2-3). In women the incidence per 10,000 was stable until 60 years of age and then declined.

Onset of symptoms was associated with a knee injury in 77 percent of the men and 64 percent of the women. This sequence was seen in all the physically active age groups in the men. In contrast, the women had a definite peak incidence in the 20-29-year-old age group (Table 2-1).

Of all the meniscal lesions operated on 73 percent were medial and 27 percent lateral. The men sustained more bucket-handle lesions than the women (Table 2-2). In the women, there was a preponderance of peripheral detachments. This discordance between men and women could not be explained solely from the different occurrence of meniscal lesions following a

knee injury. Bucket-handle lesions – in contrast to peripheral detachments – were related to trauma.

Sports injuries were responsible for 38 percent of the total number of lesions and for 52 percent of the lesions caused by a knee injury. Damage (earlier or recent) to the anterior cruciate ligament was encountered in 11 percent of the knees operated on. There was a concurrent fracture of the femoral or tibial condyles in 1.2 percent.

Total meniscectomy was performed in 79 percent of the meniscal lesions while 19 percent had a partial meniscectomy. In 0.7 percent the lesion was repaired.

Discussion

Meniscal tears do not always present with characteristic symptoms and may heal spontaneously (Noble and Hamblen 1975). Some patients accept their discomfort and do not seek medical assistance – often additionally accepting a lower level of physical performance (Hede et al. 1990a).

Epidemiological studies on meniscal lesions in adults have not been published before. In the present study the preponderance in men demonstrated in cross-sectional studies and explained by differences in exposure to trauma (Barfod and Bierring 1956, Johnson et al. 1974) has been further investigated. Reference to the background population has allowed demonstration of two different, age-related patterns of incidences in men and women.

The excess of bucket-handle lesions in men as compared with women agrees with the results of Shakespeare and Rigby (1983), and may be related to more frequent exposure to trauma. A traumatic etiology of lesions, however, did not explain this discrepancy between men and women. Little is known about biomechanical differences between male and female knee joints but varying joint laxity appears to be of no practical significance in this context (Jacobsen 1981).

In the present study the operations were performed openly. Diagnosing meniscal disorders by an arthrotomy is less accurate than when made through the arthroscope (DeHaven and Collins 1975) but meniscal lesions missed in the present study will only influence the results in patients not reoperated on. The 3 years in the early 1980's selected for study have been carefully chosen because the introduction and rapid expansion of arthroscopic surgery will prevent reliable future epidemiologic assessment, as this surgical technique is now being performed in numerous private clinics.

It appears likely that the number of surgically treated meniscus lesions has increased following the introduction of arthroscopic techniques (Abdon and Bauer 1989), because it has made possible diagnosis and minor meniscal repairs on an outpatient basis. The distribution of operations between age groups and male and females is unlikely to be affected by the technique employed.

In the present study 27 percent of the lesions were lateral. Others have found figures between 14 (Sonne-Holm et al. 1980) and 31 percent (Wynn-Parry et al. 1958). These variations are influenced by the age of the patients since the incidence of lateral meniscus tears decreases with age due to the preponderance of degenerative tears in the medial meniscus. Japanese have more lateral lesions due to more discoid lateral menisci than Europeans and Americans (Hoshikawa et al. 1983).

In children the epidemiology of meniscal lesions has been investigated by Abdon and Bauer (1989). In the present study the incidences were similar. The incidence increased fifty-fold from the first to the second decade of life. Clark and Ogden (1983) also found that meniscal injuries were uncommon in children and that the vascularity, histological characteristics and biomechanics of the developing meniscus might be responsible for this relative immunity from injury.

Above the age of 40 surgically treated meniscal lesions occurred in less than 10 per 10,000. In the same age groups Noble and Hamblen (1975) found an incidence of horizontal cleavage lesions of 29 percent in 400 menisci in a representative necropsy series indicating that a large fraction of these lesions remain unrecognized - possibly in part due to the decreased level of physical activity with increasing age.

Meniscal lesions may occur during sports (Ferguson and Thompson 1940, Sørensen and Sonne-Holm 1977). The fact that sports injuries in the present study - regarding the background population - led to more than a third of the operations, emphasizes the need for prophylactic measures (Quigley 1959).

The arthroscopic technique and the assumption that partial resection is superior to total removal (Gillquist et al. 1982, Hamberg et al. 1983a, McGinty et al. 1977) will restrict total meniscectomy and promote surgical repair.

Conclusions

The overall incidence of meniscal lesions per 10,000/year was 9.0 in men and 4.2 in women. The bucket-handle lesion was the most frequent type of meniscal lesion in men (35 percent) whereas peripheral detachment was the most frequent type in women (41 percent). The sex-associated occurrence of knee trauma causing the lesions did not explain the difference between men and women as to type of meniscal lesions. Sports injuries accounted for 38 percent of the total number of lesions.

3. Treatment in clinical practice

The menisci limit the extremes of flexion and extension (Brantigan and Voshell 1941) and absorb part of the rotational torque (Wang and Walker 1974). They are weight-bearing (Seedhom et al. 1974, Shrive 1974, Shrive et al. 1978, Seedhom 1979), transmitting 40-65 percent of the load across the joint (Krause et al. 1976). The medial meniscus is an important load-distributing structure whose function also is essential for the subchondral bone, the trabecular bone of the proximal part of the tibia and the tibial surface (Bourne et al. 1984, Odgaard et al. 1989). Menisci increase the area of weight-bearing (Kettelkamp and Jacobs 1972, Walker and Erkman 1975, Kurosawa et al. 1980, Baratz et al. 1986) and act as shock absorbers (Voloshin and Wosk 1983).

A) Meniscectomy

Meniscal function and poor clinical long term results following total meniscectomy (Bürkle-de la Champ 1935, Tapper and Hoover 1969, Jørgensen et al. 1987) suggest that the notion that the menisci are unnecessary ligamentary remnants is wrong (Seedhom 1979).

Not until recently have fibrocartilage preserving procedures such as partial meniscectomy and repair been favored (McGinty et al. 1977, Simpson et al. 1986). However, long term reviews demonstrated that partial meniscectomy does not prevent cartilage deterioration (Tapper and Hoover 1969, Appel 1970, McGinty et al. 1977). The risk of unrecognized tears and re-tears in the fibrocartilage left behind due to mechanical incongruence has been emphasized (McMurray 1941).

Despite this risk, favorable results have been reported after partial meniscectomy - both after open and arthroscopic surgery - compared to total excision (Aarstrand 1954, Böhler 1955, DiStefano 1980). These studies are all cross-sectional investigations and based on selected patients providing no data

on the course of symptoms or clinical and radiographic findings after surgery. Furthermore, which of the two procedures performed was determined by the type of lesion encountered or the preference of the surgeon (Bauer 1971, Gillquist et al. 1982). In a widely cited study by McGinty et al. (1977) no posterior horn lesions at all were treated with partial meniscectomy.

Normal preoperative radiographs and a short duration of symptoms are associated with a good prognosis (Lotke et al. 1981), provided the proper criteria are used for selection of patients (McBride et al. 1984): preexisting joint cartilage pathology and angular malalignment (Dandy and Jackson 1975a, Ferkel et al. 1985) determine the functional outcome from meniscectomy in patients over 40 years of age rather than the age itself (Lotke 1981, Northmore-Ball and Dandy 1982). Arthrosis in patients with degenerative tears is associated with a less favorable outcome (Chand 1972, Peters and Smillie 1972). Since degenerate menisci and those with undisplaced tears still transmit significant fractions of load as long as the circumferential continuity is maintained (Seedhom and Hargreaves 1979), there seems to be no advantage from excising such fibrocartilage from joints with cartilage degeneration (Jones et al. 1978, Reikerås 1989).

Meniscectomy in children is not a harmless procedure (Medlar et al. 1980, Abdon et al. 1990b). The developing meniscus seems to have greater reparative ability supporting the concept that every effort should be made to preserve some or all of a traumatized meniscus in children and adolescents (Clark and Ogden 1983).

Meniscal injury is an important consequence of both recent and old anterior cruciate ligament (ACL) tears (Galeazzi 1927, Grana et al. 1982). The incidence seems to be around 50 percent in acute injuries (Cerabona et al. 1988).

The fate of the menisci is important for the function of the ACL-insufficient knee also after reconstructional procedures (Lysholm et al. 1982, McDaniel and Dameron 1983). After partial meniscectomy the functional

outcome is best in bucket-handle lesions and worst in posterior horn lesions (Paterson and Trickey 1983). Prompt reconstruction of an ACL lesion reduces the risk of later meniscal disease (Lynch et al. 1983). Repaired menisci in ACL insufficient knees have a good chance to survive once healing has occurred (Sommerlath and Hamberg 1989, Hanks et al. 1990).

Radiological signs of degeneration after meniscectomy have been described (Huckell 1965, Appel 1970, Johnson et al. 1974, Jones et al. 1978, Yocum et al. 1979, Lotke et al. 1981, Lynch et al. 1983, Allen et al. 1984). Fairbank (1948) demonstrated three distinct varieties:

1) Anterior - posterior ridge formation downwards from the margin of the femoral condyle.
2) Narrowing of the joint space on the side of operation.
3) Generalized flattening of the marginal half of the femoral articular surface.

Joint line narrowing was related to loss of the weight bearing function of the meniscus while ridge formation and condylar flattening were thought to reflect redistribution of the load (Fairbank 1948).

Other definitions of degenerative arthritis following meniscectomy have been employed (Ahlbäck 1968) but that of Fairbank has been most widely used though is suffers from the shortcoming of including merely three radiographic signs and not defining joint line narrowing. This makes comparison between different studies difficult although a correlation between the radiographic changes and the clinical results in both sexes has been established (Tapper and Hoover 1969, Johnson et al. 1974).

Own investigations

Patients and methods

To eliminate bias in the selection of patients and clinical evaluation, we randomly allocated 200 consecutive patients to either partial or total open meniscectomy (Hede et al. 1986).

Patients with symptomatic chondromalacia of the patella, osteochondritis, ligament laxity, sequelae to patellar dislocation, and patients who previously had undergone an operation on the respective knee were excluded. All operations were performed openly. No patient had a diagnostic arthroscopy performed.

If a tear in the central three-quarters of a meniscus was disclosed peroperatively and there was no other disorder of the knee, the patient was allocated to either partial or total meniscectomy. Two hundred sealed envelopes in random order had been prepared, each containing information on which procedure to be performed, half of the envelopes indicating either procedure. Randomization was performed by peroperatively opening an envelope.

Partial meniscectomy was carried out by removing only the injured part of the meniscus, while the remainder was trimmed to make a smoothly rounded edge. Immediately after each operation the surgeon made a careful drawing of the lesion indicating the location of the fibrocartilage removed. Each lesion was classified as either bucket-handle lesion, anterior or posterior horn lesion: all longitudinal lesions were classified as bucket-handle lesions while the others were rated as either anterior or posterior horn lesions. Lesions - other than bucket-handle lesions - involving both horns were classified according to the horn more severely involved. This simple classification was chosen since it directly reflects the site of meniscal tissue removed during partial meniscectomy. Planimetric determination of the area excised from each

meniscus was made from the drawing. From this value and that of the area of the whole meniscus the percentage of meniscus surface removed was calculated.

Patients reoperated on were excluded. The remaining patients were reviewed at two months, at one year and at 7.8 years (median, range 6.3-9.8). The outcome of the operation in each patient was graded as “excellent”, “good”, “fair”, and ”poor" according to Tapper and Hoover (1969). The results from the first of these reviews disclosed no differences between the treatment groups (Hede et al. 1986) and will not be considered further. 192 patients (96 percent) accepted the invitation for a follow-up visit at one year after surgery, while 189 patients (95 percent) attended the long term follow up.

At the last interview the clinical examination was invariably performed by one investigator (AH) who had no knowledge of which operation had been performed. The Lysholm point-scoring scale (Lysholm and Gillquist 1982) adapted for meniscal lesions (Lysholm and Gillquist 1981, Hamberg et al. 1984) with a maximum score of 95 points was used for additional evaluation of knee function. This analysis comprises eight criteria: limp (5 points), support (5), giving way (20), pain (25), catching (15), swelling (10), and the ability to climb stairs (10) and to squat (5). Patients with scores above 90 points had no significant symptoms and the results were graded as excellent. Patients with scores from 77 to 90 had mild symptoms on vigorous physical activity and were graded as good. Below 77 points functional results were considered to be fair or poor. This score system was chosen since its reliability has been demonstrated (Lysholm and Gillquist 1982). The coefficient of variation has been estimated to 2.8 percent (Hamberg et al. 1984). It is suitable for computer analysis.

Patients after partial meniscectomy were stratified according to the percentage of meniscus removed into two approximately equally sized groups.

Standing anterior - posterior radiographs of both knees and unloaded lateral projections were obtained and assessed as described by Fairbank (1948).

Joint line narrowing was considered present if the difference between the knees was ≥1 mm. Patients who had been operated on in the other knee were excluded from radiographic assessment.

Statistical methods

Non-parametric methods were used: contingency table analysis, rank sum tests and Spearman's rank correlation test. The level of significance chosen was 0.05.

Short-term postoperative course

The time off work after partial meniscectomy was 6-84 days (median 23) and after total meniscectomy 7-70 days (median 27) ($0.05<P<0.1$) suggesting that the arthrotomy rather than excision of fibrocartilage is the most important operative trauma (Hede et al. 1986). This sick-leave was considerably shorter than reported earlier after open surgery (Wynn-Parry 1958, Saugmann-Jensen 1963). Patients treated with meniscectomy using closed technique have a considerably shorter period of sick leave/rehabilitation than patients treated openly (Northmore-Ball et al. 1983, Bergström et al. 1984, Hamberg et al. 1984, Simpson et al. 1986). This is due to faster recovery of muscle function (Hamberg 1983). Oretorp and Gillquist (1978) studied 18 consecutive cases of arthroscopic meniscectomy. The mean duration of sick leave was five days (median, range 0-28) after arthroscopic excision and 30 days (median, range 21-112) in controls operated on openly. Furthermore arthroscopic surgery has few complications (Sherman et al. 1986) and dysesthesia due to lesion of the prepatellar branch of the saphenous nerve is avoided (Swanson 1983). Today diagnostic arthroscopy is a minimum prerequisite for treatment of the injured knee and open meniscectomy should no longer be a treatment option. However, it has never been demonstrated that arthroscopic surgery leads to

superior long term results (Goodfellow 1983, Hamberg et al. 1984, Simpson et al. 1986).

Reoperations

Six of the patients who had a partial meniscectomy and four with a total meniscectomy were reoperated on within one year (5 percent). At the late review these figures were eight and five respectively (7 percent) - similar or lower compared to other studies on open surgery (Fox et al. 1979, Blazina et al. 1982). Most reoperations were performed within the first year, emphasizing the importance of obtaining a stable meniscal remnant after partial meniscectomy able to withstand the altered load (Grana et al. 1982, Baratz et al. 1986). The number of reoperations after arthroscopic surgery (Lysholm and Gillquist 1981) obviously also depend on the period of observation and has been estimated to 8 percent after three years and similar to that following open procedures (Whipple 1984).

The commonest finding in patients with persistent symptoms after meniscectomy is cartilage degeneration at the femoral condyles (30-40 percent) (Dandy and Jackson 1975c, Fox et al. 1979). Further meniscal pathology included retained fragments of the posterior horn (10-37 percent) and lesions of the other meniscus (2-5 percent) (Dandy and Jackson 1975c, Laasonen and Wilppula 1976, Broukhim et al. 1978, Fox et al. 1979).

Outcome from partial and total meniscectomy

Following partial meniscectomy 84 of the 92 patients (91 percent) were free of symptoms at one year (Hede et al. 1986). This is significantly more than 72 out of the 90 subjects following total meniscectomy (80 percent) (P= 0.029). At the late review 55 of the 89 (62 percent) with partial meniscectomy and 45 of the 87 patients (52 percent) with total meniscectomy had excellent results (P=0.18). However, patients with a partial meniscectomy had higher Lysholm

scores (P=0.03) (Figure 3-1) (Hede et al. 1992a). Hence, the frequency of late symptoms was not determined by the type of operation but partial meniscectomy reduced the degree of disability.

It is not clear why at one year after partial resection more patients had an excellent result than after total meniscectomy while there was no difference later. It might be speculated whether the symptoms at one year reflected the different biomechanics of the joint. Later, some knees - independently of which operation had been performed - developed degeneration sufficient to cause symptoms. The severity of symptoms being determined by the amount of fibrocartilage removed would explain the above results.

Knee joint deterioration advanced after both partial and total meniscectomy in the 175 patients attending both reviews (Table 3-1). The progressive decline in the clinical outcome is in accordance with a longitudinal study on total meniscectomy (Jørgensen et al. 1987). In that study the frequency of symptoms increased from 53 percent at 4.5 years to 67 percent at 14.5 years. The same tendency has been suggested from cross-sectional studies at different intervals after surgery (Jackson 1968, Allen et al. 1984). Our findings disagree with Gillquist et al. (1982) who described "a final level of knee joint function" after meniscectomy.

Factors related to subsequent joint impairment (Table 3-2) were:
1) Age, 2) Sex and 3) Lateral meniscus lesion (Hede et al. 1992a).

1) Lesions in younger patients are probably caused by more violent traumas with cartilage damage and minor capsular tears (Tapper and Hoover 1969). These patients expect a high level of knee joint performance and only reluctantly accept a decrease in their activity.

2) At the late examination women had worse knee joint function than men, however, only after total meniscectomy - developing between the two reviews. There is a known discrepancy in the response to meniscectomy

between men and women, men having more satisfactory results (Franke 1966, Tapper and Hoover 1969, Johnson et al. 1974).

3) Inferior functional outcome after lateral meniscectomy was observed only after total meniscectomy. Poor results following lateral meniscectomy have been described irrespective of the type of operation (Franke 1966, Johnson et al. 1974, Allen et al. 1984, Simpson et al. 1986), though not in all studies (Fischer et al. 1974).

Although the major part of the body weight is carried by the medial joint chamber at 30 degrees of knee joint flexion (Seedhom and Hargreaves 1979), the response to loss of the lateral meniscus is probably related to the fact that the lateral meniscus carries 70 percent and the medial meniscus 50 percent of the load in the respective joint chamber (Seedhom et al. 1974).

Duration of symptoms

Knee joint function did not vary with the duration of symptoms preoperatively (Hede et al. 1992a) as also reported by Jackson (1968) and Tapper and Hoover (1969). The length of history before operation has been considered one of the factors responsible for inferior results after meniscectomy (Franke 1966, Gear 1967, Johnson et al. 1974, Yocum et al. 1979) necessitating early diagnosis and removal of torn menisci (Dandy and Jackson 1975a).

Ferkel et al. (1985) investigated the correlation between duration of symptoms and clinical outcome from arthroscopic partial resection. When the degree of chondromalacia was taken into consideration there was no difference between the groups. Patients operated on within 2 months after the onset of symptoms had better results than those operated on later: this was due to a high proportion of bucket-handle lesions operated on early due to their tendency to cause knee joint locking. They have a favorable prognosis after partial meniscectomy (Tapper and Hoover 1969, Hede et al. 1992b). Thus,

presence of a tear, even for a longer period of time, does not necessarily lead to a poor functional result (Fahmy et al. 1983).

Lesion type and area of fibrocartilage removed

At partial meniscectomy 47 patients had 30 percent or less of the meniscal surface excised, while 42 had more than 30 percent removed (Hede et al. 1992b). Bucket-handle lesions had larger areas of meniscus excised than anterior and posterior horn lesions (Table 3-3). During this procedure, the wedge shape of menisci implies that successively larger portions of tissue are removed per surface unit as the capsular insertion is approached from the central edge (Figure 3-2).

Patients with posterior horn lesions had lower Lysholm scores after partial meniscectomy than patients with anterior or bucket-handle injuries (Table 3-3). Treatment of posterior horn lesions has reportedly been less successful compared to lesions in other locations (Cargill and Jackson 1976, Broukhim et al. 1978, Ferkel et al. 1985). This is due to loss of the biomechanical wedge function of the posterior horn of the medial meniscus (Levy et al. 1982, 1989) maintaining anterior - posterior and rotational stability by limiting posterior movement of the medial femoral condyle.

Our favorable results after partial meniscectomy of bucket-handle lesions (Table 3-3) are in accordance with other studies both after open and arthroscopic surgery (Lysholm and Gillquist 1981). The intra-meniscal arrangement of collagen bundles (Beaupré et al. 1986) (Figure 2-2) allows the peripheral part of the meniscus to withstand the impact of the femoral condyle (Hargreaves and Seedhom 1979). This quality is maintained in treatment of bucket-handle lesions after removal of the central part if the capsular anchorages of the anterior and posterior horns are intact (Seedhom and Hargreaves 1979, Beaupré et al. 1986).

Anterior horn tears also yielded better results than posterior horn lesions after partial meniscectomy. However, the two patients with anterior horn lesions who had more than 30 percent of the meniscal surface removed had poor functional results (Table 3-4). When the medial meniscus has large portions of its surface removed from the anterior horn, the defect is prone to involve the peripheral part of the meniscus due to the narrow configuration of the anterior horn (Burr and Radin 1982) (Figure 2-2). For the same reason, the defect will extend relatively far backwards and the situation will resemble that of leaving a posterior horn behind - a procedure that is viewed as detrimental (Johnson et al. 1974, Laasonen and Wilppula 1976).

Irrespective of the site of the tear all patients had similar scores after total meniscectomy (Table 3-4) emphasizing the uniform status of the joint after total meniscal removal. This also questions the notion that the final clinical outcome of this procedure is related to the type of lesion (Helfet 1959).

Only anterior horn tears benefited significantly from partial meniscectomy compared to total resection (Table 3-5). This again emphasizes the importance of the posterior horn since similar areas were removed in treatment of the two lesions. There was no significant difference between results following partial and total meniscectomy after bucket-handle lesions. However, a trend exists as the P value was 0.13.

Considering both partial and total meniscectomy there was a negative correlation between the portion of meniscal surface removed and knee joint function (R= -0.15, P=0.04). This is the first clinical confirmation of the experimental observations of Cox et al. (1975) - in our experience, however, this is not true for bucket-handle lesions (Hede et al. 1992b).

In patients with 30 percent or less of the meniscus surface removed the location of fibrocartilage excised did not influence the clinical outcome. In contrast, patients with 31-99 percent excised had higher scores after treatment

of bucket-handle lesions - with the peripheral rim preserved - than after anterior or posterior horn lesions (Table 3-4).

Laxity following meniscectomy

At the late review 47 percent of the patients had a slight lateral laxity - more frequently after total meniscectomy (P=0.007) and after treatment of lateral lesions (P=0.02). Stable knees had significantly higher Lysholm scores (P=0.0003). Furthermore, slight anterior - posterior instability at 90 degrees of knee flexion was seen in 28 percent of the patients - with no difference between the two treatment groups. Several retrospective reports conclude that meniscectomy may result in lateral and anterior - posterior instability (Huckell 1965, Tapper and Hoover 1969, Johnson et al. 1974).

In cadaver specimens the menisci interfere with the stability of the joint, especially when unloaded and in 10-20° of flexion (Walker and Erkman 1975, Markolf et al. 1981) and in anterior crucial ligament deficient knees (Hsieh and Walker 1976, Levy et al. 1982, Shoemaker and Markolf 1986). However, when post-meniscectomy knees were examined with a meter, Bargar et al. (1980) found that meniscectomy alone did not cause instability exceeding the normal right - left variation (Markolf et al. 1976, 1978).

Idiopathic hypermobility has been claimed to play a role for sustaining a meniscal lesion and for the results of its treatment (Stürup et al. 1987, Ferkel et al. 1985). The difference in lateral laxity between knees with partial and total meniscectomy in the present study settles the issue that the late instability is due to absence of fibrocartilage and not to initial ligamental or capsular injury.

Radiology

One year after surgery 26 percent of the patients had joint line narrowing (Table 3-6) versus 33 percent at the late review (Hede et al. 1992a). At this time 13 percent had additional ridge formation or flattening of the

femoral condyle as a sign of early knee joint degeneration. Joint space narrowing was more often seen after lateral than after medial lesions (P=0.003) in accordance with the observations of Allen et al. (1984). It was related to a high Body Mass Index, BMI = W/H^2 (patients' height (H) in meters and body weight (W) in kilograms). This suggests a high BMI as a risk factor for later joint deterioration. At both reviews there was no radiological difference between patients with partial and total meniscectomy. No association was found between radiological signs of knee joint degeneration and the location of lesion or the portion of meniscus removed.

Post meniscectomy radiology is in agreement with other reports (Saugman-Jensen 1963, Jackson 1968, Appel 1970, Johnson et al. 1974) but not with that of Veth (1985). Allen et al. (1984) found arthrosis after medial meniscectomy directly related to the degree of varus deformity in the contralateral knee.

B) Meniscal repair

Meniscal repair is limited to the area supplied from a perimeniscal capillary plexus - its blood supply originating from the capsular tissue. Fifty percent or more of the meniscus in the newborn is vascularized but has decreased to roughly 30 percent at the age of 40 (Arnoczky and Warren 1982, Clark and Ogden 1983, Day et al. 1985, Bird and Sweet 1988) with the highest blood flows at the periphery and in the anterior and posterior horns (Swiontkowski et al. 1988, Danzig et al. 1983).

For many years meniscal repair was considered a procedure of historic interest only (Aarstrand 1954), but is now a procedure of practical significance. Meniscus suture was reintroduced by Stone (1979). Both new and old vertical lesions can heal after this procedure (DeHaven 1981, 1985, Hamberg et al. 1983b). The open surgical technique includes direct exposure of the tear through a postero-medial or postero-lateral approach, suturing the meniscus to

the peripheral vascular bed and joint capsule followed by 4-6 weeks of post-operative immobilization.

Arthroscopic repair of vertical peripheral meniscal lesions was performed as early as 1980 (Scott et al. 1986). Various instrumentations (Barber and Stone 1985) have been employed. The suturing can be performed as an "outside - inside" or "inside - outside" technique depending on the course of the suture. Serious complications include injury to the peroneal nerve and popliteal artery. A narrow peripheral rim will improve meniscal repair (Scott et al. 1986). As with the open procedure, the arthroscopic repair must be followed by 4-6 weeks of immobilization.

The proportion of successfully repaired meniscal lesions apparently does not vary between open and arthroscopic procedures (Table 3-7). The open technique reduces the number of structures sutured by mistake. At the other hand the closed procedure reduces the surgical trauma.

In fresh human cadaver knees the immediate biomechanical consequences of open versus closed arthroscopic repair were investigated - with no difference demonstrated between the procedures (Baratz et al. 1988). It has been suggested that an open procedure be used within 3 mm from the meniscosynovial junction and arthroscopic techniques when repairing 3 to 5 mm from the meniscosynovial junction (DeHaven et al. 1989).

C) Non-operative treatment

In some patients with a history, symptoms and clinical findings suggesting a meniscal lesion (Hede and Hejgaard 1981, Anderson and Lipscomb 1986) symptoms disappear with no treatment. This can be explained in three different ways:

1) Spontaneous healing of the lesion. This is conceivable in undisplaced lesions in the periphery of the fibrocartilage (Arnoczky and Warren 1983). Its occurrence has been documented clinically (Wirth 1981).

2) The presumptive diagnosis is erroneous.

3) Amelioration of symptoms in spite of a persisting lesion. This is likely to occur in patients who have limited their physical performance. Spontaneous variations in the anatomy of the tear may also influence the symptoms (Shakespeare and Rigby 1983). Finally, lesions may be "silent" (Noble and Hamblen 1975).

The spontaneous course may be modified during conservative treatment - e. g. exercise programs or cast application. Non-operative treatment has been reported successful in 55 to 85 percent of patients after six weeks to five years of observation (Cravener and MacElroy 1941, Scheidegger et al. 1975).

Own investigations

Patients and methods

The study included 36 patients referred to a department of orthopedic surgery from general practitioners with symptoms and clinical findings suggesting isolated meniscal disease (Hede et al. 1990a). Thirty-two of the patients had pain in the knee, 16 suffered from intermittent swelling of the joint brought on by physical activity. Eight reported on one or two episodes of locking while three had repeated giving-way of the knee.

All knees had joint line tenderness without pain on femoral - patellar compression. They were stable with normal radiology. Thus, no patients with signs suggestive of chondromalacia of the patella, ligament insufficiency, or arthrosis were included. Orthopedic specialists recorded the history, performed the clinical examination, made the preliminary diagnosis of isolated meniscal disease and the indication for arthroscopy. The patients were given no instructions to follow a particular regimen.

Patients who waited for less than six months and those who had previous symptoms in the knee were not included. Patients with persistent swelling, a locked knee, or more than two episodes of locking had preference on the waiting list and had arthroscopy performed within six months.

We chose not to enroll patients prospectively as this would have biased the surgeons when diagnosing a meniscal lesion. The patients answered a questionnaire on the duration of symptoms after they were placed on the waiting list, as well as on changes in sports activity and ability to work. They were asked to describe their present symptoms as worse, same, partially relieved, or not present any longer with regard to changes from when they were put on the waiting list. Those who had total relief of symptoms were asked when the symptoms resolved. Finally, the patients were asked if they still wanted to undergo arthroscopy.

Course of symptoms

Thirty-two (89 percent) of the patients stated that they had experienced partial or complete relief of symptoms (Table 3-8). Four of them indicated no changes in symptoms while no one had worsening of symptoms. Among the 27 patients who had initially participated in sports, 23 with partial relief of symptoms or no symptoms ascribed this improvement to the reduction or abandonment of sports activities. Only two were able to continue at the same level of performance. Four patients were unable to work due to pain in the knee

although three of them described their symptoms as ameliorated by the time of arthroscopy.

Arthroscopic findings

Seven patients resigned from the waiting list while another seven canceled the arthroscopy. Of these fourteen patients, six had no symptoms, and three ascribed the improvement to having stopped sports activity. The remaining eight reported partial relief of their symptoms. Only one could participate in sports without restrictions (Table 3-8).

Arthroscopy was finally performed in 22 patients of which ten had a torn meniscus. In two patients, a healed meniscal tear was found. Four other patients had patellar chondromalacia and one patient had degeneration of the tibial cartilage not detectable radiographically. Five patients had a normal arthroscopy.

General considerations

Lesions of the medial collateral ligament - with no clinical laxity - occasionally mimic meniscal lesions as both often present with medial joint line tenderness and lack of extension (Brantigan and Voshell 1943, Oretorp et al. 1978, Price and Allen 1978). If no haemarthrosis develops, fracture, major capsular injury and damage to the anterior crucial ligament are unlikely. Arthroscopic establishment of meniscal lesions are not urgent if knee joint function is normalized as a torn meniscus will not be detrimental to the articular cartilage (Casscells 1981).

Arthroscopy at a later time would prevent excision of tears that would otherwise heal spontaneously (Noble and Erat 1980). Some patients are better off without arthroscopy: those without meniscal disease or other lesion that need operative treatment, and those who accept their symptoms and reduced function of the knee.

Physical therapy restore the muscular power of the knee joint and has also been recommended prior to surgery (Nicholas 1973). Healing of undisplaced peripheral lesions is facilitated if the joint is kept extended (Krause et al. 1976). In this position the contact area between femoral joint cartilage and menisci is increased with subsequent radial stabilization of the fibrocartilage during load bearing (Shrive et al. 1978) (Figure 3-2). Hence, muscular exercises should be performed isometrically.

Conservative treatment is reserved for selected cases without manifestations of impaction (Pelzl and Rueff 1969) where symptoms may improve with time - frequently caused by reduction in physical activity including sports (Hede et al. 1990a). The fact that some patients remained unfit for work emphasizes that rigidly avoiding surgery is unacceptable (Scheidegger et al. 1975). The optimum time for arthroscopy is dependent on each patient's symptoms and requirements. Waiting lists should continually be adjusted.

Conclusions

Partial meniscectomy yielded better long term functional results than did total meniscectomy, but knee joint function deteriorated after both procedures. Following partial meniscectomy posterior horn lesions had the poorest functional outcome but difference between lesion types was seen only if more than one third of the meniscal surface had been removed. The amount of meniscal tissue excised was inversely correlated to the level of knee joint function except in bucket-handle lesions treated with partial meniscectomy. Lateral laxity following meniscectomy was caused by removal of meniscal tissue and not by initial capsular or ligamental injury.

Symptoms of meniscal tears (excluding knees that have persistent swelling or frequent locking) may improve with time, but frequently the patient remains unfit for physical performance such as that needed for sports.

4. Experimental meniscal surgery

It is experimental and clinical experience that lesions in the peripheral meniscus have the ability to heal (Arnoczky and Warren 1982, Danzig et al. 1983, Hamberg et al. 1983b). In contrast, tears central to the peripheral vasculature fail to heal - even after being sutured (Heatley 1980, Cabaud et al. 1981, Veth et al. 1983a, Veth et al. 1983b, Ghadially et al. 1986).

King (1936a) stated that a torn meniscus heals with connective tissue scarring if the tear communicates with the synovial membrane. Hence, when treating new lesions the principle has been to facilitate vascular access from the periphery (Cabaud et al. 1981, Arnoczky and Warren 1983). This has been accomplished by 1) extending the lesion to the capsule (Arnoczky and Warren 1983, Veth et al. 1983a, Ghadially et al. 1986), 2) transposing a synovial flap (Veth et al. 1983b, Ghadially et al. 1986), 3) suture after excising avascular fibrocartilage between the lesion and the capsule (Heatley 1980) or 4) an implant (Tayonaga 1983, Leenslag et al. 1986, Veth et al. 1986).

Repair of old lesions has never been attempted.

Peripheral, sutured meniscal lesions have a maximum tensile strength of 80 percent of that of the opposite side (Kawai et al. 1989). Reproducing the injury causing the tears seems almost impossible. In this context experimental research will have little advantage over clinical studies. Teflon-net meniscal prosthesis caused less deterioration than did regenerate or excised menisci (Toyonaga et al. 1983) while carbon implants resulted in fiber dislocation (Veth et al. 1983b). To eliminate this problem a graft made of carbon fiber and organic polymer was used (Veth et al. 1986). The procedure was further developed by replacing the carbon with an organic polymer. Repair was evident, but no evaluation of joint cartilage was undertaken. Experimental meniscal reimplantation (Krackow and Vetter 1980, Canham and Stanish 1986) and fat pad autografts (Kohn and Wirth 1989) have reportedly been successful.

King (1936b) showed cartilage degeneration after meniscectomy to be roughly proportional to the size of the segment removed. Similar observations have been made by others but only after excision of normal fibrocartilage (Dann et al. 1969, Moskowitz et al. 1973, Cox et al. 1975, Lufti 1975, Korkala et al. 1984).

It remains unclear whether menisci can regenerate after excision (Arnoczky 1984) - possibly because of confusion as to whether partial or total meniscectomy was actually performed. Furthermore, investigations have been performed chiefly in animals. In rabbits a structure similar in shape and texture to the removed meniscus will develop after total meniscectomy (Cox et al. 1975, Kim and Moon 1979). Fibroblasts are thought to migrate into the joint from the synovium and capsule, forming a fibrous connective replacement (King 1936c, Ghosh et al. 1983). In time joint motion and load provide a proper environment for further transformation into fibrocartilage (Lufti 1975, Moon et al. 1984) whereas restrictions of knee joint activity in dogs retard the development of a regenerate (Ghosh et al. 1983). After two to four years the regenerates were similar to normal fibrocartilage (Burr and Radin 1982) and protected against joint cartilage degeneration (Elmer et al. 1977). For meniscal regeneration to occur, the excision must extend into the periphery of the meniscus where the synovium plays an important role (Elmer 1977): synovectomy at the time of meniscectomy in rabbits will prevent regrowth (Kim and Moon 1979).

Displaced meniscal lesions are known to interfere with knee joint cartilage (Shapiro and Glimcher 1980) and to increase local uptake of bone seeking radionuclides (Nicholas and Holder 1980, Mooar et al. 1987). The influence of undisplaced tears is unknown.

Preservation of normal joint cartilage is the ultimate goal in meniscal surgery but little has been published on joint cartilage reaction to meniscal repair: in dogs Kawai et al. (1989) found no macroscopic signs of cartilage degeneration three months after suture of new peripheral lesions.

Own investigations

Material and Methods

The right knees of rabbits were used for the experiments while left knees served as controls. An arthrotomy was made on the right knee joint which was approached by an anteromedial skin incision and a medial incision in the fibrous and synovial capsule. After retraction of tissues, including the extensor mechanism, a smooth-edged spatula of stainless steel was gently placed under the medial meniscus protecting the underlying cartilage. With a scalpel a 3- to 4-mm long vertical penetrating incision was made in the central avascular part of the medial meniscus at the junction of the anterior and middle third of the meniscus (Fig. 4-1). The spatula and retractors were removed, and the capsule, aponeurosis and skin incisions closed in layers with absorbable Dexon (Cyanamid of Great Britain Ltd., Hampshire) 3-0 continuous sutures (Hede et al. 1991a).

The left knee joints underwent a sham procedure i. e. arthrotomy with insertion of the spatula but without incising the meniscus. No immobilization of the joints were used. The animals were allowed to move without restriction.

Scintigraphic investigation was made 8-10 weeks after the lesion giving each rabbit an i. v. dose of 185 MBq of 99mTC-methylene diphosphonate. Between 2 and 3 h after the injection, the rabbits were anesthetized, and examined with a gamma camera (Maxi Camera, General Electric). Activity was measured over the knees. Background counting was performed over adjacent soft tissues. At least 10,000 counts were sampled in each region giving a counting error of <1 percent (Hede et al. 1989).

Further surgery was performed three months after the lesion: either medial total meniscectomy or repair of the lesion in the right knee with left sided sham operations. Meniscectomy was performed by separating the meniscus from its capsular insertion through a peripheral vertical cut with the

spatula inserted to protect the joint cartilage. Repair was performed through a full thickness radial cut with the spatula inserted. The cut extended from the lesion to the capsular insertion (Figure 4-1) cutting through the synovia. After all surgical procedures the capsule, aponeurosis and skin incisions were closed in layers with Dexon.

Three, six or nine months after the lesion the animals were killed with sodium pentobarbital. Experiment- and control knees were removed. The medial meniscus in animals that had not been meniscectomized and a piece of synovia covering the fat pad were excised for examination.

Menisci were examined with a stereo-microscope. For light microscopy, menisci and synovial tissue were fixated in 10 percent formaldehyde and processed routinely. Menisci were embedded in paraffin blocks with the plane of section approximately at a right angle to the meniscal lesion and thus parallel to the repair incision. Seven microns thick sections were stained with hematoxyline and eosine. Serial sections from the repair zone were additionally stained with toluidine-blue at pH 4 to obtain optimal metachromatic staining. Van Gieson's picrofuchsin stain was used for demonstration of collagen. Lesions were classified as healed when closure or overgrowth was seen in the stereo-microscope, and tissue transversing the defect was observed in the light-microscope.

The medial and lateral femoral and tibial condyles were examined under a stereo microscope and classified according to Shapiro and Glimcher (1980) as either normal (score = 0), with loss of glistening appearance (score = 1) or as having irregularities at the articular surface (score = 2). The condyles were placed in 10 percent neutral buffered formaldehyde, decalcified in 22 percent formic acid with 10 percent sodium citrate, and double embedded in celloidin-paraffin. Ten transverse 6μ thick sections were taken from each of the femoral and tibial condyles cutting through the area of joint cartilage where maximal stereo-microscopic abnormalities were seen. In knees with normal macroscopic

appearance specimens were obtained by cutting through the center of the cartilage at each condyle. Five specimens were stained with hematoxyline and eosine while the other five were stained with safranin O, fast green and iron hematoxyline for semiquantitative histologic-histochemical grading according to Mankin et al. (1971) (Table 4-1). The most pronounced changes as assessed microscopically in each joint cartilage were reported and the four cartilage surfaces covering the medial and lateral femoral and tibial condyles in all knees scored blindly.

The Mann-Whitney rank sum test applied on these scores were used for comparison between the treatment groups (Hede et al. 1991b).

Untreated lesions

After three and six months the lesions had not healed and there was no cellular activity near the defects (Hede et al. 1991a) in accordance with other observations (Arnoczky and Warren 1983, Veth et al. 1983a). At nine months the length of the lesion had approximately doubled, destabilizing the central part (Hede et al. 1991b). This additional splitting occurred parallel to the collagen bundles (Fig 2-2), in accordance with the theory on development of bucket-handle lesions (Shakespeare and Rigby 1983, Wirth et al. 1988).

Experimental repair

Ten three-month old avascular lesions causing proliferation of synovial cells and joint effusion were repaired and examined after three months (Hede et al. 1991a). At this time synovitis persisted while the lesions stereo-microscopically were filled with whitish, translucent material. Repair failed in one animal since the fibrocartilage central to the lesion had been detached. In another, healing was incomplete as it was only seen in the repair cut, but not in the primary lesion.

Microscopically the lesions had healed with repair tissue varying from heterogeneous cartilage to fibrous tissue. Cartilaginous areas contained intercellular substance staining heavily with toluidine-blue. The cells had rounded nuclei and were located in lacunae of varying size. The cells were densely arranged and nowhere similar to the normal surrounding meniscal tissue (Fig. 4-2).

In areas of fibrous repair with fibroblasts being the predominant cell the extracellular matrix appeared fibrillar and loosely packed, staining positively for collagen. Adjacent to normal fibrocartilage, fibroblasts were metaplastic with more rounded and chondroid appearing nuclei. In these areas, the surrounding matrix was more homogeneous, as in fibrocartilage, than in areas with spindle shaped fibroblasts but many cellular transitional forms were seen.

The area of repair was locally overgrown by a brim of vascular and synovia coated fibrotic tissue, extending from the periphery. In eight of the nine healed menisci this pannus reached the central edge of the meniscus where vessels were found. In these areas the nuclei were densely arranged. Synovitis persisted in all repaired knees.

The cartilaginous repair tissue in the present study is different from the fibrous tissue observed after immediate repair (Arnoczky and Warren 1983,

Kawai et al. 1989, Veth et al. 1983a) although scattered cartilage transformation has been reported (Ghadially et al. 1986, Heatley 1980). Cartilaginous healing found in the present study is most likely related to a marked synovial response noted at the time of repair. The significance of synovial vascular tissue for meniscal healing and regeneration has been documented (Elmer et al. 1977, Kim and Moon 1979, Moon et al. 1984, Arnoczky et al. 1988).

At the cellular level of the repair three mechanisms are of interest:

1) Synovial cells may include pluripotential cells. Transformation of synovia derived fibroblasts to fibrochondrocytes has been suggested (Ghadially et al. 1986, Heatley 1980) and would explain the variety in the cellular morphology found in the present study. The case of partial healing strongly indicates a peripheral origin of the repair tissue.

2) Proliferation of fibrochondrocytes near the lesion. Webber et al. (1985, 1989) demonstrated, that rabbit fibrochondrocytes in vitro were capable of proliferation, matrix synthesis and migration. Depending on the culture medium two different morphological types of chondrocytes appeared (Ghadially et al. 1980): polygonal or round cells appearing as typical cultured chondrocytes and more fusiform or elongated cells growing in whorled patterns. Local application of a fibrin clot has initiated fibrocartilaginous repair in avascular meniscal defects (Arnoczky et al. 1988). Still, the origin of the reparative cells was obscure. In the present study, invading synovial cells along the repair cut might produce a locally acting stimulus for proliferation of fibrochondrocytes. If this stimulus is present in insufficient amount, the healing may be mainly fibrous. This theory would explain the activity of the fibrochondrocytes overgrown by the synovial coated pannus at the inner border of the meniscus in the present study.

3) Peripheral blood elements and serum are potential sources of cells and growth factors required for fibrochondrocyte proliferation (Webber et al. 1985). If such a mechanism was present, some cellular activity near the

unrepaired lesions should be expected to react to the inevitable postoperative hemarthron.

Scintigraphy

In the eight rabbits examined increased isotope uptake was found in knees with meniscal lesions (Hede et al. 1989). This study has demonstrated, that even indisplaceable lesions in the avascular part of the meniscus affect the isotope uptake and hemodynamics of the joint. The method used in this study does not clarify the site of the enhanced isotope uptake. Autoradiography was attempted but was inconclusive (unpublished).

Joint cartilage after
1) meniscal injury

Joint cartilage reaction to an untreated lesion in the central avascular part of the medial meniscus (Figure 4-1) was studied in 12 rabbits (treatment groups U3, U6 and U9 in Table 4-2) (Hede et al. 1991b).

Three (U3) and six (U6) months after the lesion, loss of the normal glistering appearance was observed stereo-microscopically in the medial tibial cartilage while the femoral cartilage was unaffected. At nine months - when the lesions had lost their mechanical stability - these changes were now seen at the femoral condyle as well while irregularities were found at the tibial plateau.

Knees with three and six month-old lesions had pathological Mankin-scores but without significant difference. As early as three months after the lesion clefts to the transitional zone of the cartilage at the medial tibial condyle were seen demonstrating that even undisplaced meniscal lesions affect the articular cartilage to such an extent that it must be questioned whether the changes are reversible (Reimann et al. 1982). Parallel to meniscal damage after nine months the scores had increased as compared to three and six months after the lesions ($P<0.001$). Enhanced involvement of the medial femoral

condyles was seen with roughly a third of the scores being derived from the lateral chamber. The finding of more conspicuous changes at the tibial than at the femoral condyles agrees with the results of Cox and Cordell (1977), though not with their observation that a torn meniscus not interfering with normal knee joint movement does not cause degenerative changes.

2) meniscectomy

Total meniscectomy was performed in six three-month old lesions and the joints studied after another three months (Hede et al. 1991b). A meniscus regenerate was observed in five of the knees. Severe macroscopic and microscopic alterations were seen at both medial condyles demonstrating no function of the meniscus (treatment group E6 in Table 4-2). The knees were significantly more affected than when leaving the lesions untreated for three months.

Joint cartilage degeneration has been reported after resection of normal menisci (Cox and Cordell 1977) but seems to be dependent on the amount and localization of the fibrocartilage removed (Bruce and Walmsley 1937, Moskowitz et al. 1973). For this reason partial meniscectomy was not considered. The present study has allowed comparison with repaired and non-treated lesions.

3) meniscal repair

Three months old lesions resulting in moderate synovitis and cartilage deterioration were repaired. The outcome was compared to that after non-treatment and meniscectomy (Hede et al. 1991b).

Six months after the lesions there was no difference in Mankin scores between repaired and untreated lesions (Table 4-2). Meniscectomized joints showed further joint damage.

Nine months after the meniscal lesion, repaired knees (treatment group R9) had lower scores than untreated joints (treatment group U9). There was no difference between scores from knees with repaired lesions at six (treatment group R6) and nine months (treatment group R9). Knees in these treatment groups had similar condylar contribution to the Mankin score. In R6 the contribution of the medial femoral condyle apparently exceeded that observed in U6 where normal function of the medial meniscus should be expected. Such difference would be explained either from 1) An abnormal mechanical contact between the condyle and the edge of the surrounding meniscal tissue, or 2) Interference with cartilage nutrition due to changes in pressure on the cartilage at the site of repair (Moskowitz et al. 1973).

The Mann-Whitney test was applied to the scores from each of the four condyles in the experiment knees (Hede et al. 1991b). Using aggregated scores of each animal in the analysis generated similar results.

Meniscal repair of avascular lesions in the present study benefited knees in which further meniscal injury would otherwise develop but the procedure did not reverse the cartilage changes noted at the time of treatment. Synovitis observed after repair demonstrates that this procedure does not represent the ideal therapeutic solution: the repair cut interferes with the load bearing capacity of the meniscus by interrupting the continuity of the peripheral part (Seedhom and Hargreaves 1979). Shrive et al. (1978) have reported that the hoop tension (Krause et al. 1976, Fithian et al. 1989) is lost when a single radial cut is made to the capsular margin and that it is equivalent to meniscectomy as far as load bearing is concerned. In accordance, repaired peripheral radial lesions do not function normally in terms of load-bearing (Krause et al. 1989) in contrast to longitudinal lesions (Newman et al. 1989).

Conclusions

Three-month old stable meniscal lesions affected joint cartilage both macro- and microscopically and caused abnormal scintigraphy.

A method for repair of three-month old meniscal lesions was presented. The lesions healed mainly with cartilaginous tissue although the repaired areas were different from the normal fibrocartilage.

Joint cartilage changes after meniscectomy were more pronounced than after meniscal repair or in untreated lesions. However, meniscal repair did not reverse the cartilage alterations. Meniscal repair benefited knees in which further meniscal injury would otherwise develop.

Summary

The epidemiology of meniscal lesions was analyzed in a suburban area of Copenhagen with approximately 620,000 inhabitants. The overall incidence of meniscal lesions per 10,000 inhabitants per year was 9.0 in men and 4.2 in women. The highest incidences were seen in the 3rd, 4th and 5th decade of age. In men onset of symptoms was more often related to trauma than in women (77 vs. 64 percent). Bucket-handle lesion was the most frequent type of meniscal lesion in men (35 percent) whereas most peripheral detachments (41 percent) occurred in women. The sex-associated occurrence of knee trauma did not explain the difference between men and women as to type of meniscal lesions.

To compare the clinical, functional and radiological outcome after partial and total meniscectomy 200 patients participated in a prospective and randomized study. They were peroperatively allocated to one of the two open procedures. The results were compared at one year and at 6.3-9.8 years (median 7.8).

After one year more patients with partial meniscectomy (91 percent) than with total meniscectomy (80 percent) had no complaints. At the late review this difference was not observed, but patients with partial meniscectomy had the highest functional scores. In 5 percent knee joint function had improved and in 35 percent deteriorated, in the latter group with no difference between partial and total meniscectomy.

The incidence of lateral laxity rose from 8 to 47 percent and occurred more frequently after total meniscectomy. During the observation period radiological signs of knee joint degeneration changed from solely joint line narrowing into additional ridge formation and flattening of the femoral condyle, but unrelated to whether partial or total meniscectomy had been performed.

Following partial meniscectomy posterior horn lesions had the poorest functional outcome but difference in scores between lesions types was seen only if more than one third of the meniscal surface had been removed. The amount of meniscal tissue excised was inversely correlated to knee joint function except in bucket handle lesions treated with partial meniscectomy. These lesions had the largest areas of meniscal tissue removed but higher functional scores than posterior horn lesions. Preservation of the peripheral rim of the meniscus following partial meniscectomy was essential for the functional outcome after surgery.

The course of symptoms and sports performance was investigated in 36 patients. They were waiting for an arthroscopy of the knee joint due to symptoms suggesting an isolated meniscal lesion. Six to 24 months after being placed on the waiting list, none of the patients noted worsening of symptoms, four had no change and nine had no symptoms. Twenty-three others had improved but 17 had stopped sports or reduced sports activity while only two of the 27 who did sports before they had knee joint symptoms had resumed their normal activity. By the time of admission, 14 patients refused arthroscopy; eight had decided to give up sports indefinitely. Of the 22 patients who underwent arthroscopy, meniscal pathology was demonstrated in 12 cases. In two of these a healed meniscal lesion was found. It was concluded that symptoms of meniscal tears of knees may improve with time, but frequently the patient remains unfit for physical performance such as that needed for sports.

An experimental model for repair of three months old longitudinal and stable lesions in the central avascular portion of the rabbits meniscus was presented: three months after a longitudinal incision in the avascular portion no healing was observed. At that time repair was performed by a full thickness radial cut from the lesion to the joint capsule. Three months later, 9 of 10 menisci had healed mainly with cartilaginous tissue although the repaired

areas both at gross inspection and histologically were different from the normal fibrocartilage. It is suggested that synovitis with hyperplasia of the lining cells - present in all cases at the time of repair - plays an important role in the healing process.

The articular cartilage of the rabbits' knees was studied at three-month intervals after the lesion. Joint cartilage was affected both macro- and microscopically after three months. Scintigraphy was abnormal in all. Meniscal repair did not reverse the cartilage alterations seen at the time of repair, but benefited knees in which further meniscal damage would otherwise develop. Joint cartilage changes after meniscectomy were more pronounced than after meniscal repair or in untreated lesions.

Summary in Danish

Meniskoperationer hører til de hyppigst udførte ortopædkirurgiske indgreb, men meget lidt vides om forekomsten af menisklæsioner i en population. I afhandlingens epidemiologiske del blev 1.215 meniskoperationer gennemgået. Incidencen af kirurgisk behandlet menisklæsion per 10.000 indbyggere var 9.0 for mænd og 4.2 for kvinder. Læsionstyperne var forskellige hos mænd og kvinder, men dette forklaredes ikke af kønsvariationen af traumatisk betingede læsioner. 38 percent af læsionerne opstod under sportsudøvelse.

Antagelsen om, at partiel excision giver bedre langtidsresultater end total meniskektomi, hviler på efterundersøgelser, hvor det udførte indgreb ofte har været bestemt af læsionstypen. Derfor deltog 200 patienter med menisklæsion i et prospektivt studie og blev peroperativt randomiseret til partiel eller total meniskektomi. Et år efter operationen var flest partielt opererede symptomfri. Efter 7.8 år kunne denne forskel ikke påvises, men de partielt opererede havde bedst knæfunktion. Yngre patienter, kvinder og patienter med laterale menisklæsioner havde særlig risiko for et dårligt funktionelt resultat. Endvidere påvistes, at læsionstypen påvirker resultatet af partiel meniskektomi, men kun hvis mere end 30 percent af menisken fjernes.

For at belyse spontanforløbet hos patienter med symptomer på menisklæsion fulgtes patienter, som ventede på artroskopi for menisklæsion. Efter 6 - 24 måneder var 89 percent helt eller delvist symptomfri, mens kun 7 percent kunne genoptage sport.

I afhandlingens dyreeksperimentelle del præsenteres en metode til reparation af mekanisk stabile læsioner i den avaskulære meniskdel med øget isotopoptagelse ved 99mTC-methylene-diphosphonat skintigrafi. Efter reparation helede læsionerne hovedsageligt med fibrocartilago, som dog aldrig var mikroskopisk identisk med normalt meniskvæv. Ledbrusken i knæled hos

kaniner med tre måneder gamle menisklæsioner blev undersøgt makro- og mikroskopisk med tre-måneders intervaller efter reparation, meniskektomi samt efter undladelse af behandling. Reparation normaliserede ikke forandringerne i ledbrusken på reparationstidspunktet men forhindrede yderligere ødelæggelse af menisken. De mest udtalte ledbruskforandringer fandtes efter meniskektomi.

Tables

Age groups	0-19	20-29	30-39	40-49	≥50	All ages
Males	83	83	80	71	64	77
Females	71	81	61	61	51	64
All	77	83	75	68	57	73

Table 2-1: Traumatic origin (percentages) of meniscal lesions in 1,215 patients according to sex and age groups.

Types of lesion	Bucket-handle	Peripheral	Horizontal	Parrot-beak	Contusion	Others	Total
Males	35$	31#	2.5	14	4.0	14	100
Females	21$	41#	3.0	12	7.0	16	100
Traumatic	35$	34	2.2	12	3.5	13	100
Non-traumatic	18$	35	3.7	15	8.8	20	100
All	30	34	2.6	13	4.9	15	100

Table 2-2: Classification (percentages) of 1,215 meniscal lesions according to sex and trauma. Meniscal cysts, discoid tears, and meniscal lesions that could not be classed are grouped as "Others" ($: P<0.001, #: P<0.01).

Functional Group	**Poor**	**Fair**	**Good**	**Excellent**
Short term 1 year	1	1	26	147
Long term median 7.8 years	3	20	53	99

Table 3-1: Functional grouping in 175 non-reoperated patients after partial or total meniscectomy.

Levels changed	**-3**	**-2**	**-1**	**0**	**+1**	**+2**	**+3**
Patients	2	14	45	105	8	1	0

Table 3-2: Changes in functional levels "excellent", "good", "fair" and "poor" from short to long term review in 175 patients after partial or total meniscectomy. "-" indicates changes to a lower functional group. "+" indicates changes to a higher functional group.

Type of lesion	**Anterior horn**	**Bucket-handle**	**Posterior horn**
Number	22	42	25

Percentage of meniscus surface removed			
Median	21	38.5 *	22
Range	12-34	15-71	10-65
Scores			
Median	95	95	90 §
Range	58-95	76-95	62-95

Table 3-3: Percentage of removed meniscus surface and Lysholm scores in 89 patients treated with partial meniscectomy. (*: P<0.001, §: P=0.016).

Type of lesion	**Anterior horn**	**Bucket-handle**	**Posterior horn**
Partial meniscectomy (1-30 percent of meniscus surface removed)			
Number	20	11	16
Median score	**95**	**95**	**90**
Range of score	58-95	88-95	62-95
Partial meniscectomy (31-99 percent of meniscus surface removed)			
Number	2	31	9
Median score	**78**	**95** *	**89**
Range of score	75, 81	76-95	62-95
Total meniscectomy (100 percent of meniscus surface removed)			
Number	24	33	30
Median score	**90**	**90**	**90**
Range of score	58-95	64-95	55-95

Table 3-4: Lysholm scores in 176 patients treated with partial or total meniscectomy for meniscal lesions of different locations in relation to portion of meniscus surface removed. (*: P=0.003).

Functional group	Poor-Fair	Good	Excellent	Total
Anterior horn P=0.02				
partial meniscectomy	3 (13.6)	6 (27.3)	13 (59.1)	22 (100)
total meniscectomy	6 (25.0)	12 (50.0)	6 (25.0)	24 (100)
Bucket-handle P=0.13				
partial meniscectomy	1 (2.4)	15 (35.7)	26 (61.9)	42 (100)
total meniscectomy	5 (15.2)	12 (36.4)	16 (48.5)	33 (100)
Posterior horn P=0.94				
partial meniscectomy	3 (12.0)	15 (60.0)	7 (28.0)	25 (100)
total meniscectomy	6 (20.0)	14 (46.7)	10 (33.3)	30 (100)
Total	24 (13.6)	74 (42.1)	78 (44.3)	176 (100)

Table 3-5: Functional grouping according to Lysholm in 176 patients at 7.8 years (median) after partial or total meniscectomy in treatment of different types of meniscal lesions. Figures in parenthesis indicate percentages.

	Short term review one year		**Long term review** median 7.8 years	
Operation performed	**Partial meniscectomy** (92 patients)	**Total meniscectomy** (90 patients)	**Partial meniscectomy** (73 patients)	**Total meniscectomy** (70 patients)
Condyle Ridge	0	0	7	10
Joint line narrowing	25	22	21	26
Condyle Flattening	0	0	1	1

Table 3-6: Number of patients showing radiographic changes according to Fairbank at one year and at median 7.8 years after partial or total meniscectomy.

Author	A/O	Knees +/- ACL	Follow-up (months)	Healed (percent)	P. O. P. I. (weeks)
Stone 1979	O	22 +	0-48	91	4
Wirth 1981	O	10 -	24	100	6
Cassidy and Shaffer 1981	O	29 -	6-17	93	6
Hamberg et al. 1983b	O	50 +	18	84	5
Hendler 1984	A	8 +	>6	100	6
Muri et al. 1986	O	22 -	5-42	73	6
Scott et al. 1986	A	178 +	28-231	79	8
Keene et al. 1987	A	48 +	13-30	98	6
Jakob et al. 1988	A	54 -	25	78	5-6
Miller 1988	A	79 +	12-66	91	6
DeHaven et al. 1989	O	80 +	24-108	89	4-6
Morgan et al. 1989	A	74 +	2-24	84	?
Sommerlath and Hamberg 1989	O	28 +	72-96	89	5
Hanks et al. 1990	A/O	23 +	56	87	4-6

Table 3-7: Benchmarks of 14 reports on meniscal repair: “A” indicates arthroscopic repair and “O” indicates open repair while + or - after the number of treated knees indicates whether or not the material includes patients with lesions of the anterior cruciate ligament (ACL). P. O. P. I.: Post Operative Period of Immobilization.

	Same symptoms	Partial relief	No symptoms	Total
Never sports	2 (2)	4 (4)	2	8 (6)
Normal activity	0	2 (1)	0	2 (1)
Reduced activity	1 (1)	5 (3)	0	6 (4)
Stopped	1 (1)	12 (7)	6 (3)	19 (11)
Started	0	0	1	1
Total	4 (4)	23 (15)	9 (3)	36 (22)

Table 3-8: Sports activity in relation to altered knee joint symptoms in 36 patients who had a diagnosis of a suspected meniscal lesion. (): Patients who eventually had an arthroscopy.

	Grade		Grade
I. Structure		**III. Safranin-O staining**	
a. Normal	0	a. Normal	0
b. Surface irregularities	1	b. Slight reduction	1
c. Pannus and surface irregularities	2	c. Moderate reduction	2
d. Clefts to transitional zone	3	d. Severe reduction	3
e. Clefts to radial zone	4	e. No dye noted	4
f. Clefts to calcified zone	5		
g. Complete disorganization	6		
II. Cells			
a. Normal	0		
b. Diffuse hypercellularity	1	**IV. Tidemark integrity**	
c. Cloning	2	a. Intact	0
d. Hypocellularity	3	b. Crossed by blood vessels	1

Table 4-1: Histological-histochemical grading of joint cartilage from serial sections stained with hematoxyline and eosine and safranin-O-fast green-iron hematoxyline. From Mankin et al. (1971).

TREATMENT GROUPS	**U3**	**R6**	**E6**	**U6**	**R9**	**U9**	**Total**
Examined knees	**3 (3)**	**6 (2)**	**6 (1)**	**6 (2)**	**6 (4)**	**3 (3)**	**30 (15)**
MACROSCOPIC SCORES							
Medial tibial cartilage	1 (0)	1 (0)	2 (0)	1 (0)	1.5 (0)	2 (0)	
Medial femoral cartilage	0 (0)	0 (0)	1 (0)	0 (0)	0 (0)	1 (0)	
MICROSCOPIC SCORES		*	*/**	**	***	***	
Cumulated score for each knee	6 (2)	8	19	8	12 (0)	18 (2)	
	6 (2)	8 (1)	15	9	10 (2)	14 (1)	
	8 (2)	5	20	7 (1)	8 (1)	18 (3)	
		8	30	7 (1)	8		
		9 (1)	37 (1)	6	10		
		6	21	10	6 (0)		
Percentual contribution to cumulated score							
Medial tibial cartilage	80	68	44	73	67	40	
Lateral tibial cartilage	10	21	12	21	20	20	
Medial femoral cartilage	10	11	34	6	11	26	
Lateral femoral cartilage	0	0	10	0	2	14	
Total number of knees	**6**	**8**	**7**	**8**	**10**	**6**	**45**

Table 4-2: Macroscopic and microscopic morphological cartilage scores in 30 experiment knees and 15 control knees (in parentheses) from 30 rabbits treated for an experimental meniscal lesion in the right medial meniscus.
Knees examined: 3 months after a meniscal lesion (U3), 6 months after a meniscal lesion repaired after 3 months (R6), 6 months after a meniscal lesion treated with total meniscectomy after 3 months (E6), 6 months after a meniscal lesion (U6), 9 months after a meniscal lesion repaired after 3 months (R9), 9 months after a meniscal lesion (U9). For further details see text. (* and **: $P<0.001$, ***: $P=0.001$).

Figures with legends

(The printed figures exist as glossy photographs)

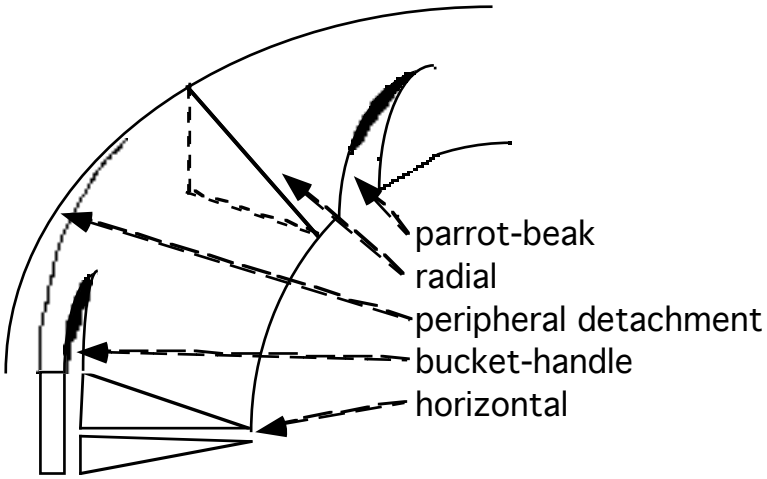

Figure 2-1: Classification of meniscal lesions.

Figure 2-2: Collagen fiber orientation in the right medial and the lateral meniscus viewed from above.

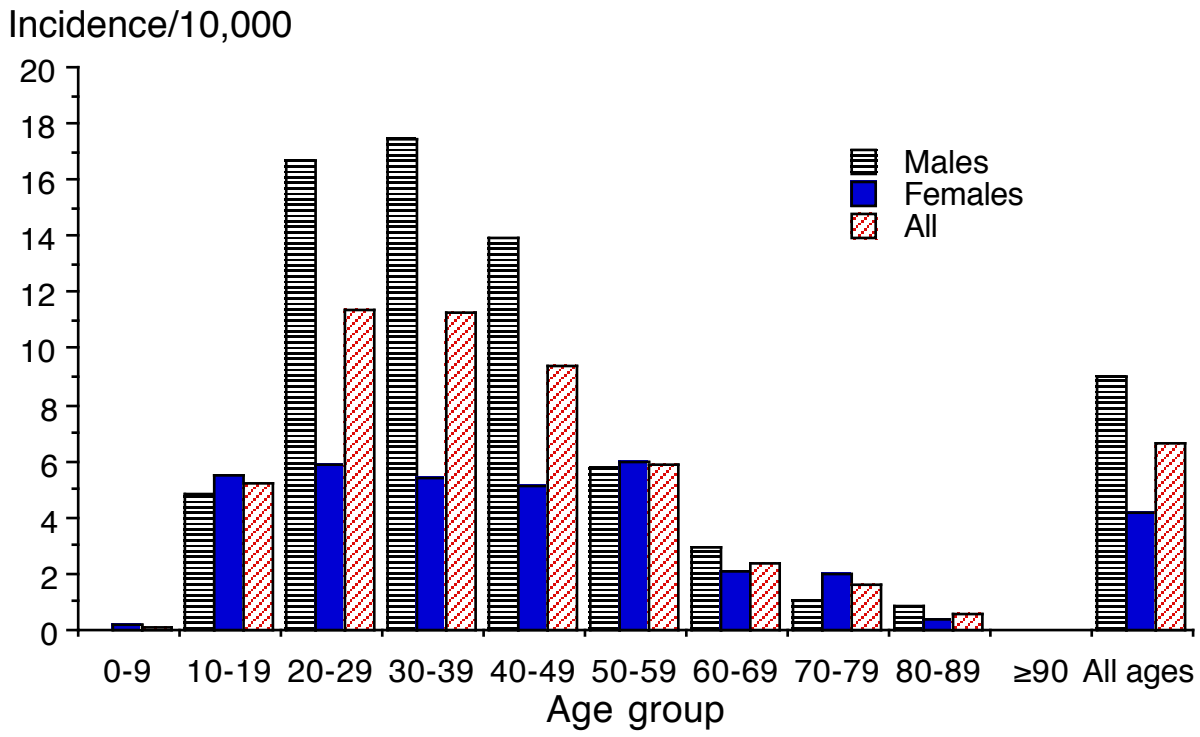

Figure 2-3: Incidences per year per 10,000 inhabitants of surgically treated meniscal lesions in Copenhagen County during the period 1982-1984.

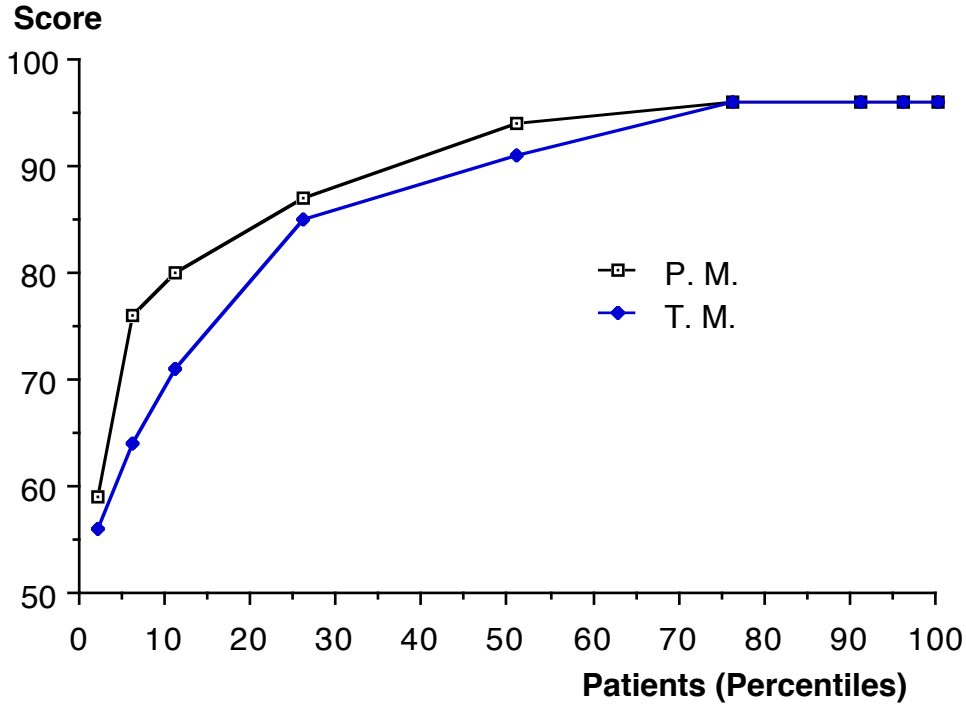

Figure 3-1: Lysholm Score in 89 patients with partial meniscectomy (P. M.) and 87 patients with total meniscectomy (T. M.) at a median of 7.8 years after surgery.

Figure 3-2: Forces acting on the meniscus during load bearing with ensuing radial stabilization and resulting force acting towards the periphery. (t_f: force from the femoral condyle, t_t: force from the tibial condyle, t_r: resultant force acting on the meniscus). The size of the arrows is imaginary. Redrawn from Wirth et al. (1988).



Figure 4-1: a) Position of lesion in the right medial meniscus. b) Position of lesion and repair cut in the right medial meniscus.

Figure 4-2: Wedge section of repair zone with cartilaginous tissue and normal adjoining meniscus (Stain, toluidine blue; original magnification, x 250).

Figure 4-3: Surface irregularities, cleft formation and slight reduction of safranin-O staining in joint cartilage from the medial tibial condyle in a knee with a repaired three-month old lesion inspected 6 months after the lesion (Group R6). (Stain, safranin O, fast green and iron hematoxyline; original magnification, x 100).

References

Aarstrand T. Treatment of Meniscal Rupture of the Knee Joint. Acta Chir Scand 1954; 107: 146-157.

Abdon P, Bauer M. Incidence of meniscal lesions in children. Acta Orthop Scand 1989; 60: 710-711.

Abdon P, Lindstrand A, Thorngren K-G. Statistical evaluation of the diagnostic criteria for meniscal tears. Internat Orthop 1990a; 14: 341-345.

Abdon P, Turner M S, Pettersson H, Lindstrand A, Stenström A, Swanson A J G. A long-term follow up study of total meniscectomy in children. Clin Orthop 1990b; 257: 166-170.

Ahlbäck S. Osteoarthrosis of the knee: A radiographic investigation. Acta Radiol 1968; Suppl 277: 7-71.

Allen P R, Denham R A, Swan A V. Late degenerative changes after meniscectomy. J Bone Joint Surg 1984; 66-B: 666-671.

Anderson A F, Lipscomb A B. Clinical diagnosis of meniscal tears. Am J Sports Med 1986; 14: 291-293.

Annandale T. An operation for displaced semilunar cartilage. Br Med J 1885; 1: 779.

Appel H. Late results after meniscectomy in the knee joint. Acta Orthop Scand Suppl 1970; 133.

Arnoczky S P. Meniscal healing, regeneration, and repair. Advan Orthop Surg 1984; 5: 244-252.

Arnoczky S P, Warren R F. Microvasculature of the human meniscus. Am J Sports Med 1982; 10: 90-95.

Arnoczky S P, Warren R F. The microvasculature of the meniscus and its response to injury. Am J Sports Med 1983; 11: 131-141.

Arnoczky S P, Warren R F, Spivak J M. Meniscal repair using an exogenous fibrin clot. J Bone Joint Surg 1988; 70-A: 1209-1217.

Baratz M E, Fu F H, Mengato R. Meniscal tears: The effect of meniscectomy and of repair on intraarticular contact areas and stress in the human knee. Am J Sports Med 1986; 14: 270-275.

Baratz M E, Rehak D C, Fu F H, Rudert M J. Peripheral tears of the meniscus. The effect of open versus arthroscopic repair on intraarticular contact stresses in the human knee. Am J Sports Med 1988; 16: 1-5.

Barber F A, Stone R G. Meniscal Repair, an arthroscopic technique. J Bone Joint Surg 1985; 67-B: 39-41.

Barfod B, Bierring F. Treatment of Lesions of the Semilunar Cartilages. Acta Chir Scand 1956; 110: 422-435.

Bargar W L, Moreland J R, Markolf K L, Shoemaker S C, Amstutz H C, Grant T T. In vivo stability testing of post-meniscectomy knees. Clin Orthop 1980; 150: 247-252.

Bauer R. Ein Beitrag zur Frage der Total- oder Teilresektion bei traumatischen Meniscusläsionen. Arch Orthop Unfall-Chir 1971; 69: 341-350.

Beaupré A, Choukroun R, Guidouin R, Garneau R, Gérardin H, Cardou A. Knee Menisci - Correlation Between Microstructure and Biomechanics. Clin Orthop 1986; 208: 72-75.

Bergström R, Hamberg P, Lysholm J, Gillquist J. Comparison of open and endoscopic meniscectomy. Clin Orthop 1984; 184: 133-136.

Bird M D T, Sweet M B E. Canals in the semilunar meniscus: Brief report. J Bone Joint Surg 1988; 70-B: 839.

Blazina M E, Fox J M, Del Pizzo W, Friedman M J, Ivey F M. Thomas B. Quigley, M.D., and the Meniscus. Clin Orthop 1982; 164: 84-92.

Bourne R B, Finlay J B, Papadopoulos P, Andreae P. The Effect of Medial Meniscectomy on Strain Distribution in the Proximal Part of the Tibia. J Bone Joint Surg 1984; 66-A: 1431-1437.

Böhler L. Behandlung, Nachbehandlung und Begutachtung von Meniscusverletzungen. Erfahrungen an 1000 operierten Fällen. Arch Klin Chir 1955; 282: 264-276.

Brantigan O C, Voshell A F. The mechanics of the ligaments and menisci of the knee joint. J Bone Joint Surg 1941; 23: 44-66.

Brantigan O C, Voshell A F. The tibial collateral ligament: Its function, its bursae, and its relation to the medial meniscus. J Bone Joint Surg 1943; 25: 121-131.

Broukhim B, Blazina M E, Fox J M, Del Pizzo W. Retained Posterior Horn of the Medial Meniscus. Clin Orthop 1978; 136: 188-190.

Bruce J, Walmsley R. Replacement of the semilunar cartilages of the knee after operative excision. Br J Surg 1937; 25: 17-28.

Bullough P G, Munuera L, Murphy J, Weinstein A M. The strength of the menisci of the knee as it relates to their fine structure. J Bone Joint Surg 1970; 52-B: 564-570.

Burr D B, Radin E L. Meniscal Function and the Importance of Meniscal Regeneration in Preventing Late Medial Compartment Osteoarthrosis. Clin Orthop 1982; 171: 121-125.

Bürkle-de la Camp H. Aussprache. Zentral Blatt für Chir 1935; 1: 49.

Cabaud H E, Rodkey W G, Fitzwater J E. Medial meniscus repairs. Am J Sports Med 1981; 9: 129-134.

Canham W, Stanish W. A study of the biological behavior of the meniscus as a transplant in the medial compartment of a dog's knee. Am J Sports Med 1986; 14: 376-379.

Cargill A O'R, Jackson J P. Bucket-Handle Tear of the Medial Meniscus. J Bone Joint Surg 1976; 58-A: 248-251.

Casscells S W. The torn meniscus and degenerative joint disease. Trans Am Academy Orthop Surg 1981; 5: 400.

Cassidy R E, Shaffer A J. Repair of peripheral meniscus tears. Am J Sports Med 1981; 9: 209-214.

Cerabona F, Sherman M F, Bonamo J R, Sklar J. Patterns of meniscal injury with acute anterior cruciate ligament tears. Am J Sports Med 1988; 6: 603-609.

Chand K. Horizontal (cleavage) tears of the knee-joint in the elderly. Am J Geriatr Soc 1972; 9: 430-433.

Clark C R, Ogden J A. Development of the Menisci of the Human Knee Joint. J Bone Joint Surg 1983; 65-A: 538-547.

Cox J S, Cordell L D. The degenerative effects of medial meniscus tears in dogs´ knees. Clin Orthop 1977; 125: 236-242.

Cox J S, Nye C E, Schaefer W W, Woodstein I J. The degenerative effects of partial and total resection of the medial meniscus in dogs' knees. Clin Orthop 1975; 109: 178-183.

Cravener E K, MacElroy D G. Injuries of the internal semilunar cartilage. J Am Med Assoc 1941; 117: 1695-1700.

Dandy D J. The arthroscopic anatomy of symptomatic meniscal lesions. J Bone Joint Surg 1990; 72-B: 628-633.

Dandy D J, Jackson R W. Meniscectomy and Chondromalacia of the Femoral Condyle. J Bone Joint Surg 1975a; 57-A: 1116-1119.

Dandy D J, Jackson R W. The impact of arthroscopy on the management of disorders of the knee. J Bone Joint Surg 1975b; 57-B: 346-348.

Dandy D J, Jackson R W. The diagnosis of problems after meniscectomy. J Bone Joint Surg 1975c; 57-B: 349-352.

Daniel D, Daniels E, Aronson D. The diagnosis of meniscus pathology. Clin Orthop 1982; 163: 218-224.

Dann P, Haike H, Rosenbauer K. Experimentelle Untersuchungen zur Frage der totalen oder partiellen Meniscusresektion. Arch Orthop Unfall Chir 1969; 65: 209-219.

Danzig L, Resnick D, Gonsalves M, Akeson W H. Blood supply to the normal and abnormal menisci of the human knee. Clin Orthop 1983; 172: 271-276.

Day B, Mackenzie W G, Shim S S, Leung G. The vascular and nerve supply of the human meniscus. Arthroscopy 1985; 1: 58-62.

DeHaven K E. Peripheral meniscus repair. An alternative to meniscectomy. Trans Am Academy Orthop Surg 1981; 5: 399-400.

DeHaven K E. Meniscus repair in the athlete. Clin Orthop 1985; 198: 31-35.

DeHaven K E, Black K P, Griffiths H J. Open meniscus repair. Technique and two to nine year results. Am J Sports Med 1989; 17: 788-795.

DeHaven K E, Collins H R. Diagnosis of Internal Derangements of the Knee. J Bone Joint Surg 1975; 57-A: 802-810.

DiStefano V J. Function, Post-Traumatic Sequelae and Current Concepts of Management of Knee Meniscus Injuries. Clin Orthop 1980; 151: 143-146.

Elmer R M, Moskowitz R W, Frankel V H. Meniscal regeneration and postmeniscectomy degenerative joint disease. Clin Orthop 1977; 124: 304-310.

Fahmy N R M, Williams E A, Noble J. Meniscal pathology and osteoarthritis of the knee. J Bone Joint Surg 1983; 65-B: 24-28.

Fairbank T J. Knee joint changes after meniscectomy. J Bone Joint Surg 1948; 30-B: 664-670.

Ferguson K L, Thompson W D. Internal derangements of the knee joint. Ann Surg 1940; 112: 454-470.

Ferkel R D, Davis J R, Friedman M J, Fox J M, Pizzo W D, Snyder S J, Berasi C C. Arthroscopic partial medial meniscectomy: An analysis of unsatisfactory results. Arthroscopy 1985; 1: 44-52.

Fischer V, Bruns H, Matzen K. Belastbarkeit nach medialer und lateraler Meniskektomie. Wehrmed Mschr 1974; 12: 370-374.

Fithian D C, Schmidt M B, Ratcliffe A, Mow V C. Human meniscus tensile properties: Regional variation and biochemical correlation. Trans Orthop Res Soc 1989; 35: 205.

Fox J M, Blazina M E, Carlson J. Multiphasic view of medial meniscectomy. Am J Sports Med 1979; 7: 161-164.

Franke J V. Arthrosis deformans und Meniskusoperation. Beitr Orthop 1966; 13: 89-96.

Galeazzi R. Clinical and experimental study of lesions of the semilunar cartilages of the knee joint. J Bone Joint Surg 1927; 9: 515-523.

Gear M W L. The late results of meniscectomy. Br J Surg 1967; 54: 270-272.

Ghadially F N, Lalonde J M-A, Yong N K. Myofibroblasts and intracellular collagen in torn semilunar cartilages. J Submicrosc Cytol 1980; 12: 447-455.

Ghadially F N, Wedge J H, Lalonde J-M A. Experimental methods of repairing injured menisci. J Bone Joint Surg 1986; 68-B: 106-110.

Ghosh P, Sutherland J M, Taylor T K F, Pettit G D, Bellenger C R. The effects of postoperative joint immobilization on articular cartilage degeneration following meniscectomy. J Surg Res 1983; 35: 461-473.

Gillies H, Seligson D. Precision in the Diagnosis of Meniscal Lesions: A Comparison of Clinical Evaluation, Arthrography, and Arthroscopy. J Bone Joint Surg 1979; 61-A: 343-346.

Gillquist J, Hamberg P, Lysholm J. Endoscopic partial and total meniscectomy. Acta Orthop Scand 1982; 53: 975-979.

Goodfellow J. W. He who hesitates is saved. J Bone Joint Surg 1980; 62-B: 1-2.

Goodfellow J W. Closed meniscectomy, Editorial. J Bone Joint Surg 1983; 65-B: 373-374.

Grana W A, Connor S, Hollingsworth S. Partial arthroscopic meniscectomy. Clin Orthop 1982; 164: 78-82.

Hamberg P. Treatment of meniscus lesions in the knee. Linköping university med dissert 1983; 156.

Hamberg P, Gillquist J, Lysholm J. Suture of new and old peripheral meniscus tears. J Bone Joint Surg 1983b; 65-A: 193-197.

Hamberg P, Gillquist J, Lysholm J. A comparison between arthroscopic meniscectomy and modified open miniscectomy. J Bone Joint Surg 1984; 66-B: 189-192.

Hamberg P, Gillquist J, Lysholm J, Öberg B. The effect of diagnostic and operative arthroscopy and open meniscectomy on muscle strength in the thigh. Am J Sports Med 1983a; 11: 289-292.

Hamilton A S, Finklestein H E. The result of meniscectomy (knee joint) in soldiers. Southern Med J 1943; 36: 406-411.

Hanks G A, Gause T M, Handal J A, Kalenak A. Meniscus repair in the anterior cruciate deficient knee. Am J Sports Med 1990; 18: 606-613.

Hargreaves D J, Seedhom B B. On the "bucket handle" tear: partial or total meniscectomy? A quantitative study. J Bone Joint Surg 1979; 61-B: 381.

Heatley F W. The meniscus-can it be repaired? J Bone Joint Surg 1980; 62-B: 397-402.

Hede A, Hejgaard N. Menisklæsionens diagnostik. Værdien af klinisk knæundersøgelse. Ugeskr Laeg 1981; 39: 2495-2497.

Hede A, Hejgaard N, Larsen E. Partial or total open meniscectomy? A prospective, randomized study. Internat Orthop 1986; 10: 105-108.

Hede A, Hempel-Poulsen S, Jensen J S. Symptoms and level of sports activity in patients awaiting arthroscopy for meniscal lesions of the knee. J Bone Joint Surg 1990a; 72-A: 550-552.

Hede A, Jensen D B, Blyme P, Sonne-Holm S. Epidemiology of meniscal lesions in the knee. Acta Orthop Scand 1990b; 61(5): 435-437.

Hede A, Larsen E, Sandberg H. Partial versus total meniscectomy. A prospective, randomised study with long-term follow-up. J Bone Joint Surg 1992a;74-B:118-121.

Hede A, Larsen E, Sandberg H. The long term outcome of open total and partial meniscectomy related to the quantity and site of the meniscus removed. Internat Orthop 1992b;16: 122-125.

Hede A, Madsen J, Svalastoga E, Bülow J. Radionuclide uptake in experimentally induced meniscal lesions in rabbit knees. Acta Vet Scand 1989; 30: 229-230.

Hede A, Svalastoga E, Reimann I. Repair of three-month-old experimental meniscal lesions in rabbits. Clin Orthop 1991a; 266: 238-243.

Hede A, Svalastoga E, Reimann I. Articular cartilage changes following meniscal lesions. Repair and meniscectomy studied in the rabbit knee. Acta Orthop Scand 1991b; 62(4): 319-322.

Helfet A J. Mechanism of derangements of the medial semilunar cartilage and their management. J Bone Joint Surg 1959; 41-B: 319-336.

Helfet A J. Disorders of the knee. 1974; J B Lippincott Co. Philadelphia.

Hendler R C. Arthroscopic meniscal repair. Clin Orthop 1984; 190: 163-169.

Hoshikawa Y, Kurosawa H, Fukubayashi T, Nakajima H, Watarai K. The prognosis of meniscectomy in athletes. Am J Sports Med 1983; 11: 8-13.

Hsieh H-H, Walker P S. Stabilizing Mechanisms of the Loaded and Unloaded Knee Joint. J Bone Joint Surg 1976; 58-A: 87-93.

Huckell J R. Is meniscectomy a benign procedure? Can J Surg 1965; 8: 254-260.

Ireland J, Trickey E L, Stoker D J. Arthroscopy and arthrography of the knee. J Bone Joint Surg 1980; 62-B: 3-6.

Jackson J P. Degenerative Changes in the Knee after Meniscectomy. Brit Med J 1968; 2: 525-527.

Jacobsen K. Gonylaxometry. Stress radiographic measurement of passive stability in the knee joints of normal subjects and patients with ligament injuries. Acta Orthop Scand 1981; Suppl 194: 1-263.

Jakob R P, Stäubli H U, Zuber K, Esser M. The arthroscopic meniscal repair. Am J Sports Med 1988; 2: 137-142.

Johnson R J, Kettelkamp D B, Clark W, Leaverton P. Factors Affecting Late Results after Meniscectomy. J Bone Joint Surg 1974; 56-A: 719-729.

Jones R E, Smith E C, Reisch J S. Effects of Medial Meniscectomy in Patients Older than Forty Years. J Bone Joint Surg 1978; 60-A: 783-786.

Jørgensen U, Sonne-Holm S, Lauridsen F, Rosenklint A. Long-term follow-up of meniscectomy in athletes. J Bone Joint Surg 1987; 69-B: 80-83.

Kawai Y, Fukubayashi T, Nishino J. Meniscal Suture. An experimental study in the dog. Clin Orthop 1989; 243: 286-293.

Keene G C R, Paterson R S, Teague D C. Advances in arthroscopic surgery. Clin Orthop 1987; 224: 64-70.

Kettelkamp D B, Jacobs A W. Tibiofemoral Contact Area - Determination and Implications. J Bone Joint Surg 1972; 54-A: 349-356.

Kim J-M, Moon M-S. Effect of Synovectomy upon Regeneration of Meniscus in Rabbits. Clin Orthop 1979; 141: 287-294.

King D. The healing of semilunar cartilages. J Bone Joint Surg 1936a; 18: 333-342.

King D. The function of semilunar cartilages. J Bone Joint Surg 1936b; 18: 1069-1076.

King D. Regeneration of the semilunar cartilage. Surg Gyn Obstet 1936c; 62: 167-170.

Kohn D, Wirth C J. Meniscus replacement using a fat pad autograft. Proceedings of the International Society of the Knee. Am J Sports Med 1989; 17: 724.

Korkala O, Karaharju E, Grönblad M, Aalto K. Articular cartilage after meniscectomy. Acta Orthop Scand 1984; 55: 273-277.

Krackow K A, Vetter W L. Surgical reimplantation of the medial meniscus and repair of meniscal lacerations: An experimental study in dogs. Trans Orthop Res Soc 1980; 5: 128.

Krause W R, Burdette W A, Loughran T P. Properties of the normal and repaired meniscus. Trans Orthop Res Soc 1989; 35: 207.

Krause W R, Pope M H, Johnson R J, Wilder D G. Mechanical Changes in the Knee after Meniscectomy. J Bone Joint Surg 1976; 58-A: 599-604.

Kreiner S. Analysis of multidimensional contingency tables by exact conditional tests: Techniques and strategies. Scand J Statist 1987; 14: 97-112.

Kurosawa H, Fukobayashi T, Nakajima H. Load-Bearing Mode of the Knee Joint: Physical Behavior of the Knee Joint with or Without Menisci. Clin Orthop 1980; 149: 283-290.

Laasonen E M, Wilppula E. Why a meniscectomy fails. Acta Orthop Scand 1976; 47: 672-675.

Leenslag J W, Pennings A J, Veth R P H, Nielsen H K L, Jansen H W B. A porous composite for reconstruction of meniscal lesions. Biological and Biomechanical Performance of Biomaterials. In: Christel P, Meunier A, Lee A J C (eds.): Biological and biomechanical performance of biomaterials. 1986; Elsevier. Amsterdam.

Levinsohn E M, Baker B E. Prearthrotomy Diagnostic Evaluation of the Knee. Am J Roentgenol 1980; 134: 107-111.

Levy I M, Torzilli P A, Gould J D, Warren R F. The effect of lateral meniscectomy on motion of the knee. J Bone Joint Surg 1989; 71-A: 401-406.

Levy I M, Torzilli P A, Warren R F. The effect of medial meniscectomy on anterior - posterior motion of the knee. J Bone Joint Surg 1982; 64-A: 883-888.

Lidge R T. Meniscal derangement: Unusual cases. Orthop Clin North Am 1979; 10: 659-670.

Lotke P A, Lefkoe R T, Ecker M L. Late results following Medial Meniscectomy in an Older Population. J Bone Joint Surg 1981; 63-A: 115-119.

Lufti A M. Morfological changes in the articular cartilage after meniscectomy. J Bone Joint Surg 1975; 57-B: 525-528.

Lynch M A, Henning C E, Glick K R. Knee Joint Surface Changes - Long-term Follow-up Meniscus Tear Treatment in Stable Anterior Cruciate Ligament Reconstructions. Clin Orthop 1983; 172: 148-153.

Lysholm J, Gillquist J. Endoscopic Meniscectomy. Internat Orthop 1981; 5: 265-270.

Lysholm J, Gillquist J. Evaluation of knee ligament surgery results with special emphasis on use of a scoring scale. Am J Sports Med 1982; 10: 150-154.

Lysholm J, Gillquist J, Liljedahl S-O. Arthroscopi in the early diagnosis of injuries to the knee joint. Acta Orthop Scand 1981; 52: 111-118.

Lysholm J, Gillquist J, Liljedahl S-O. Long - term results after early treatment of knee injuries. Acta Orthop Scand 1982; 53: 109-118.

Mankin H J, Dorfman H, Lippiello L, Zarins A. Biochemical and metabolic abnormalities in articular cartilage from osteo-arthritic human hips. J Bone Joint Surg 1971; 53-A: 523-537.

Markolf K L, Bargar W L, Shoemaker S C, Amstutz H C. The Role of Joint Load in Knee Stability. J Bone Joint Surg 1981; 63-A: 570-585.

Markolf K L, Graff-Radford A, Amstutz H C. In vivo knee stability. A quantitative assessment using an instrumented clinical testing apparatus. J Bone Joint Surg 1978; 60-A: 664-674.

Markolf K L, Mensch J S, Amstutz H C. Stiffness and laxity of the knee - The contribution of supporting structures. J Bone Joint Surg 1976; 58-A: 583-594.

McBride G G, Constine R M, Hofmann A A, Carson R W. Arthroscopic Partial Medial Meniscectomy in the Older Patient. J Bone Joint Surg 1984; 66-A: 547-551.

McDaniel W J, Dameron Jr. T B. The Untreated Anterior Cruciate Ligament Rupture. Clin Orthop 1983; 172: 158-163.

McGinty J B, Geuss L F, Marvin R A. Partial or total meniscectomy. J Bone Joint Surg 1977; 59-A: 763-766.

McMurray T P. The semilunar cartilages. Br J Surg 1941; 29: 407-414.

Medlar R C, Mandiberg J J, Lyne E D. Meniscectomies in children. Am J Sports Med 1980; 8: 87-92.

Miller D B. Arthroscopic meniscus repair. Am J Sports Med 1988; 4: 315-320.

Mooar P, Gregg J, Jacobstein J. Radionuclide imaging in internal derangements of the knee. Am J Sports Med 1987; 15: 132-137.

Moon M-S, Kim J-M, Ok I-Y. The Normal and Regenerated Meniscus in Rabbits. Morphologic and histologic studies. Clin Orthop 1984; 182: 264-269.

Morgan C D, Wojtys E M, Casscells C D, Casscells S W. Arthroscopic meniscus repair evaluated by second look arthroscopy. Proceedings of the International Society of the Knee. Am J Sports Med 1989; 17: 724-725.

Moskowitz R W, Davis W, Sammarco J, Martens M, Baker J, Mayor M, Burstein A H, Frankel V H. Experimentally induced degenerative joint lesions following partial meniscectomy in the rabbit. Arthritis Rheum 1973; 16: 397-405.

Muri R, Birkeland S, Mølster A O. Sutur av isolert perifer meniskløsning. Tidsskr Nor Lægeforen 1986; 106: 2985-2986.

Newman A P, Anderson D R, Daniels A U, Dales M C. Mechanics of the healed meniscus in a canine model. Am J Sports Med 1989; 17: 164-175.

Nicholas J A, Freiberger R H, Killoran P J. Double-Contrast Arthrography of the Knee. J Bone Joint Surg 1970; 52-A: 203-220.

Nicholas J A. Injuries to the menisci of the Knee. Orthop Clin North Am 1973; 4: 647-664.

Nicholas J A, Holder L E. Bone imaging in orthopaedic medicine. 1980; ProClinical. New York

Noble J, Erat K. In defence of the meniscus. J Bone Joint Surg 1980; 62-B: 7-11.

Noble J, Hamblen D L. The pathology of the degenerate meniscus lesion. J Bone Joint Surg 1975; 57-B: 180-186.

Northmore-Ball M D, Dandy D J. Long-term Results of Arthroscopic Partial Meniscectomy. Clin Orthop 1982; 167: 34-42.

Northmore-Ball M D, Dandy D J, Jackson R W. Arthroscopic, open partial, and total meniscectomy. J Bone Joint Surg 1983; 65-B: 400-404.

Odgaard A, Pedersen C M, Bentzen S M, Jørgensen J, Hvid I. Density Changes at the Proximal Tibia After Medial Meniscectomy. J Orthop Res 1989; 7(5): 744-753.

Oretorp N, Alm A, Ekström, Gillquist J. Immediate effects of meniscectomy on the knee joint. Acta Orthop Scand 1978; 49: 407-414.

Oretorp N, Gillquist J. Partial meniscectomy preferred. Br Med J 1978; 6129: 55.

Passariello R, Trecco F, de Paulis F, Masciocchi C, Bonanni G, Zobel B B. Meniscal lesions of the knee joint: CT Diagnosis. Radiology 1985; 157: 29-34.

Paterson F W N, Trickey E L. Meniscectomy for tears of the meniscus combined with rupture of the anterior cruciate ligament. J Bone Joint Surg 1983; 65-B: 388-390.

Pelzl H, Rueff F L. Operative und konservative Behandlung der Meniskusverletzungen. Münsch Med Wschr 1969; 2: 74-79.

Perey O. Follow-up results of meniscectomy with regard to the working capacity. Acta Orthop Scand 1962; 32: 457-460.

Peters T J, Smillie I S. Studies on the chemical composition of the menisci of the knee joint with special reference to the horizontal clevage lesion. Clin Orthop 1972; 86: 245-252.

Price, C T, Allen W C. Ligament Repair in the Knee with Preservation of the Meniscus. J Bone Joint Surg 1978; 60-A: 61-65.

Quigley T B. Knee injuries incurred in sport. J A M A 1959; 171: 1666-1670.

Raunest J, Oberle K, Loehnert J, Hoetzinger H. The clinical value of magnetic resonance imaging in the evaluation of meniscal disorders. J Bone Joint Surg 1991; 73-A: 11-16.

Reikerås O. Arthroscopic resection of meniscal flaps of the knee. Acta orthop Scand 1989; 60: 28-29.

Reimann I, Christensen S B, Diemer N H. Observations of reversibility of glycosaminoglycan depletion in articular cartilage. Clin Orthop 1982; 168: 258-264.

Roper B A, Levack B. The arthrogram in the diagnosis of meniscal lesions in the fourth decade of life. Clin Orthop 1986; 210: 213-215.

Saugmann-Jensen J. Knæets Menisklæsioner. Thesis 1963; Munksgaard, Copenhagen.

Scheidegger A, Küpfer K, Stirnemann H. Spätresultate bei nicht operierten Patienten mit Verdacht auf Meniskusläsion. Helv Chir Acta 1975; 42: 485-488.

Schmidt H. Knæledsartrografi. Diagnostiske muligheder ved dobbelt-kontrast-metoden. Thesis 1982; FADL, Copenhagen.

Scott G A, Jolly B L, Henning C E. Combined Posterior Incision and Arthroscopic Intra-Articular Repair of the Meniscus. J Bone Joint Surg 1986; 68-A: 847-861.

Seedhom B B. Transmission of the load in the knee joint with special reference to the role of the menisci. Part I. IMechE 1979; 8: 207-219.

Seedhom B B, Dawson D, Wright V. Functions of the menisci-a preliminary study. J Bone Joint Surg 1974; 56-B: 381-382.

Seedhom B B, Hargreaves D J. Transmission of the load in the knee joint with special reference to the role of the menisci. Part II. IMechE 1979; 8: 220-228.

Shakespeare D T, Rigby H S. The bucket-handle tear of the meniscus. J Bone Joint Surg 1983; 65-B: 383-387.

Shapiro F, Glimcher M J. Induction of osteoarthrosis in the rabbit knee joint. Clin Orthop 1980; 147: 287-295.

Shermann O H, Fox J M, Snyder S J, Del Pizzo W, Friedman M J, Ferkel R D, Lawley M J. Arthroscopy - "No-problem surgery". J Bone Joint Surg 1986; 68-A: 256-265.

Shoemaker S C, Markolf K L. The Role of the Meniscus in the Anterior-Posterior Stability of the Loaded Anterior Cruciate-Deficient Knee. J Bone Joint Surg 1986; 68-A: 71-79.

Shrive, N. The weight-bearing role of the menisci of the knee. J Bone Joint Surg 1974; 56-B: 381.

Shrive N G, O`Connor J J, Godfellow J W. Load-Bearing in the Knee Joint. Clin Orthop 1978; 131: 279-287.

Simpson D A, Thomas N P, Aichroth P M. Open and closed meniscectomy. J Bone Joint Surg 1986; 68-B: 301-304.

Smillie I S. The current pattern of internal derangements of the knee joint relative to the menisci. Clin Orthop 1967; 51: 117-122.

Smillie I S. Degenerative lesions of the menisci. J Bone Joint Surg 1977; 59-B: 100-101.

Sommerlath K, Hamberg P. Healed meniscal tears in unstable knees. Am J Sports Med 1989; 17: 161-163.

Sonne-Holm S, Fledelius I, Ahn N C N. Results after meniscectomy in 147 athletes. Acta Orthop Scand 1980; 51: 303-309.

Sørensen C H, Sonne-Holm S. Akutte idrætsskader. Ugeskr Laeg 1977; 139: 2593-2595.

Stone R G. Peripheral detachment of the menisci of the knee: A preliminary report. Orthop Clin North Am 1979; 10: 643-657.

Stürup J, Iversen B F, Lauersen N. Abnormal knee mobility and meniscal injury. Acta Orthop Scand 1987; 58: 655-657.

Swanson A J G. The incidence of prepatellar neuropathy following medial meniscectomy. Clin Orthop 1983; 181: 151-153.

Swiontkowski M F, Schlehr F, Sanders R, Limbird T A, Pou A, Collins J C. Direct, real time measurement of meniscal blood flow. Am J Sports Med 1988; 16: 429-433.

Tapper E M, Hoover N W. Late Results after Meniscectomy. J Bone Joint Surg 1969; 51-A: 517-526.

Toyonaga T, Uezaki N, Chikama H. Substitute Meniscus of Teflon-net for the Knee Joint of Dogs. Clin Orthop 1983; 179: 291-297.

Veth R P H. Clinical Significance of the Knee Joint Changes After Meniscectomy. Clin Orthop 1985; 198: 56-60.

Veth R P H, Den Heeten G J, Jansen H W B, Nielsen H K L. Repair of the meniscus. An experimental investigation in rabbits. Clin Orthop 1983a; 175: 258-262.

Veth R P H, Den Heeten G J, Jansen H W B, Nielsen H K L. An Experimental Study of Reconstructive Procedures in Lesions of the Meniscus. Clin Orthop 1983b; 181: 250-254.

Veth R P H, Jansen H W B, Leenslag J W, Pennings A J, Hartel R M, Nielsen H K L. Experimental Meniscal Lesions Reconstructed With a Carbon Fiber-polyurethane-poly(L-lactide) graft. Clin Orthop 1986; 202: 286-293.

Voloshin A S, Wosk J. Shock absorption of meniscectomized and painful knees: A comparative in vivo study. J Biomed Eng 1983; 5: 157-161.

Wagner H-J. Die Kollagenfaserarchitektur der Menisken des menschlicen Kniegelenkes. Z Mikrosk Anat Forsch 1976; 2: 302-324.

Walker P S, Erkman M J. The role of the Menisci in Force Transmission Across the Knee. Clin Orthop 1975; 109: 184-192.

Wang C-J, Walker P S. Rotatory Laxity of the Human Knee Joint. J Bone Joint Surg 1974; 56-A: 161-170.

Webber R J, Harris M G, Hough A J Jr. Cell culture of rabbit meniscal fibrochondrocytes: Proliferative and synthetic response to growth factors and ascorbate. J Orthop Res 1985; 3: 36-42.

Webber R J, York J L, Vanderschilden J L, Hough A J. An organ culture for assaying wound repair of the fibrocartilaginous knee joint meniscus. Am J Sports Med 1989; 17: 393-400.

Whipple T L, Caspari R B, Meyers J F. Arthroscopic Meniscectomy. An Interrim Report at Three to Four Years After Operation. Clin Orthop 1984; 183: 105-114.

Wirth C R. Meniscus Repair. Clin Orthop 1981; 157: 153-160.

Wirth C J, Rodriguez M, Milachowski K A. Meniskusnaht - Meniskusersatz. 1988; Georg Thieme Verlag. Stuttgart.

Wynn-Parry C B, Nichols P J R, Lewis N R. Meniscectomy. A review of 1723 cases. Ann Phys Med 1958; 4: 201-215.

Yocum L A, Kerlan R K, Jobe F W, Carter V S, Shields jr C L, Lombardo S J, Collins H R. Isolated lateral meniscectomy. J Bone Joint Surg 1979; 61-A: 338-342.