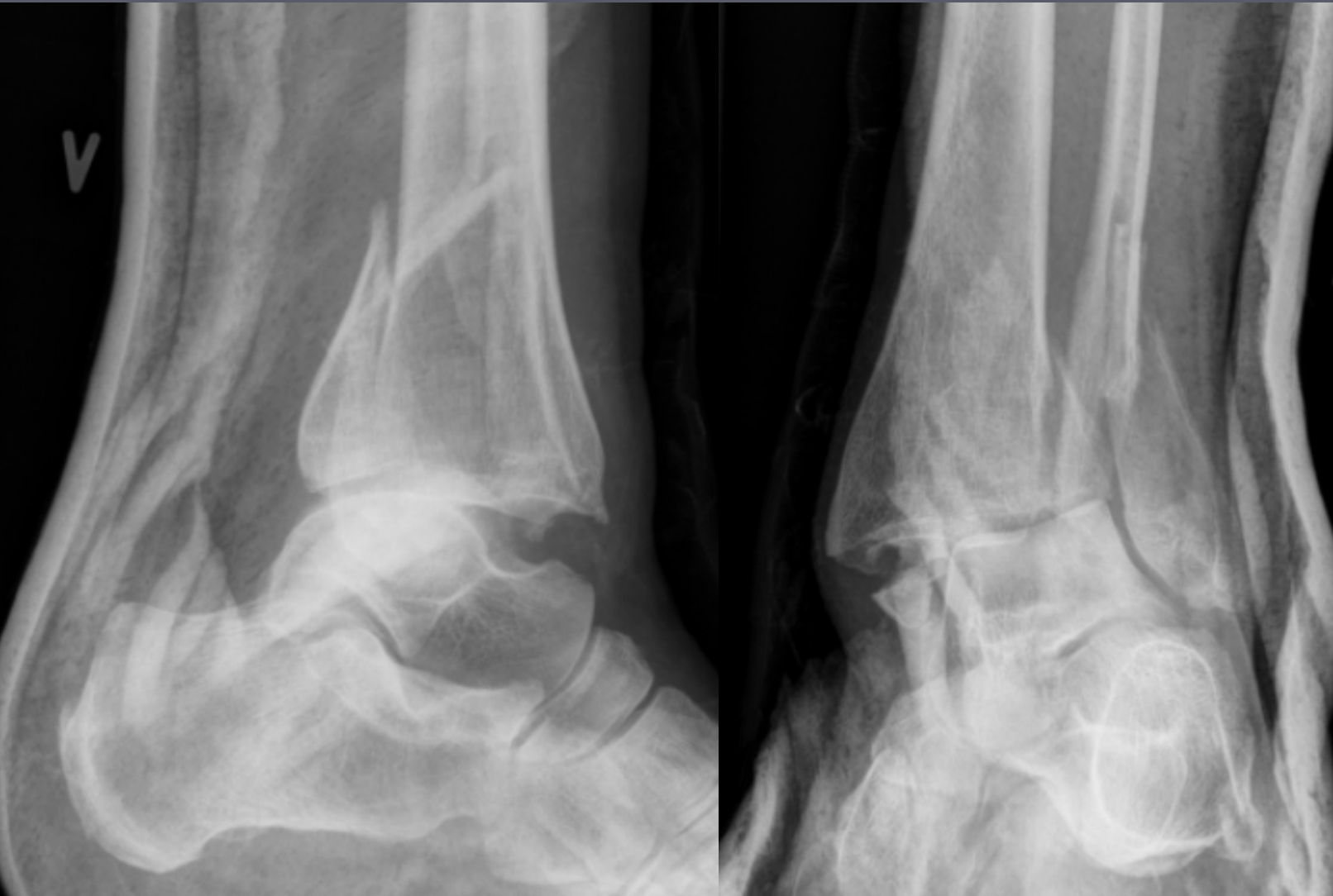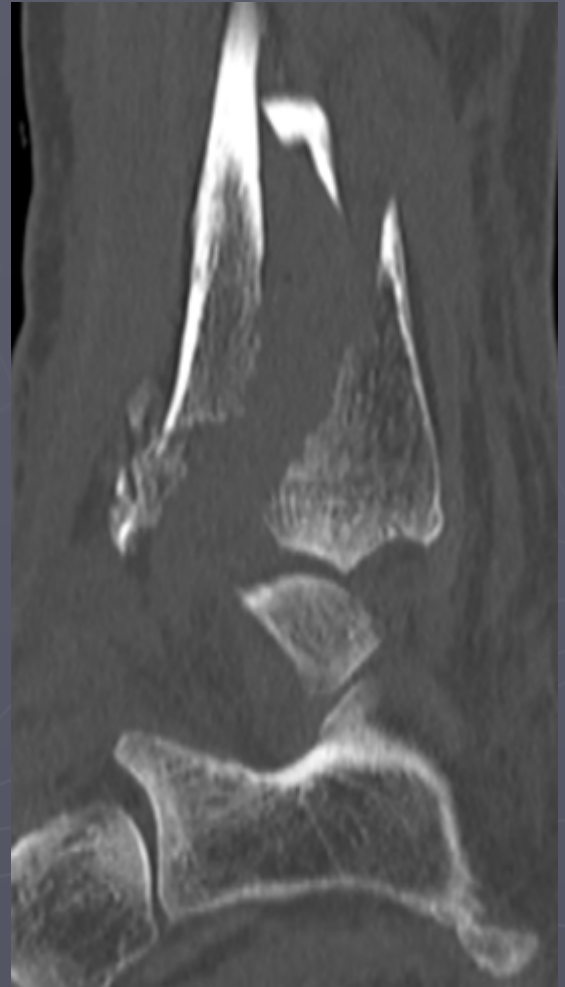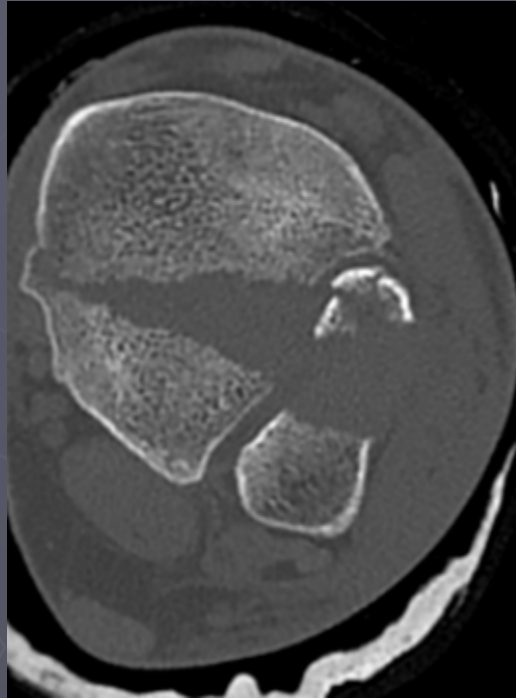
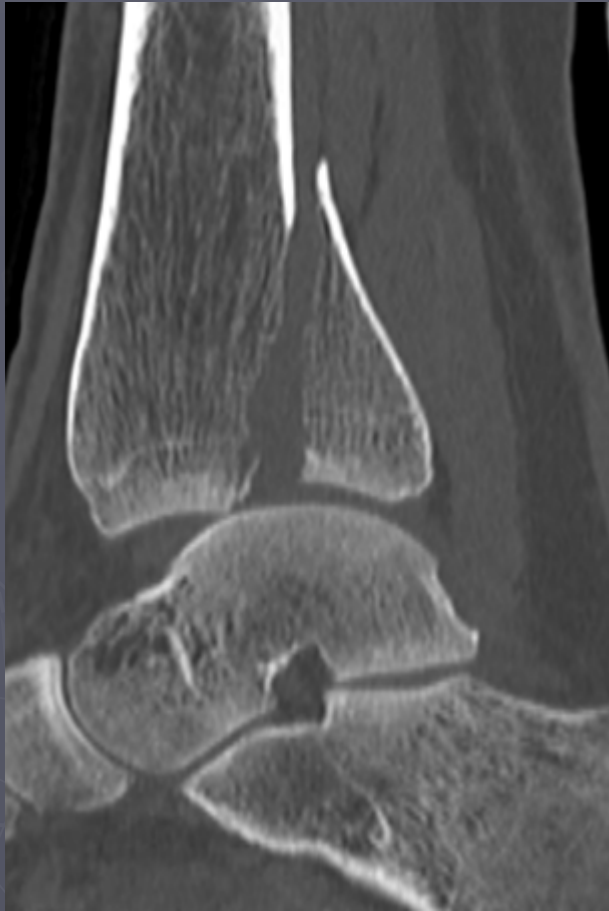
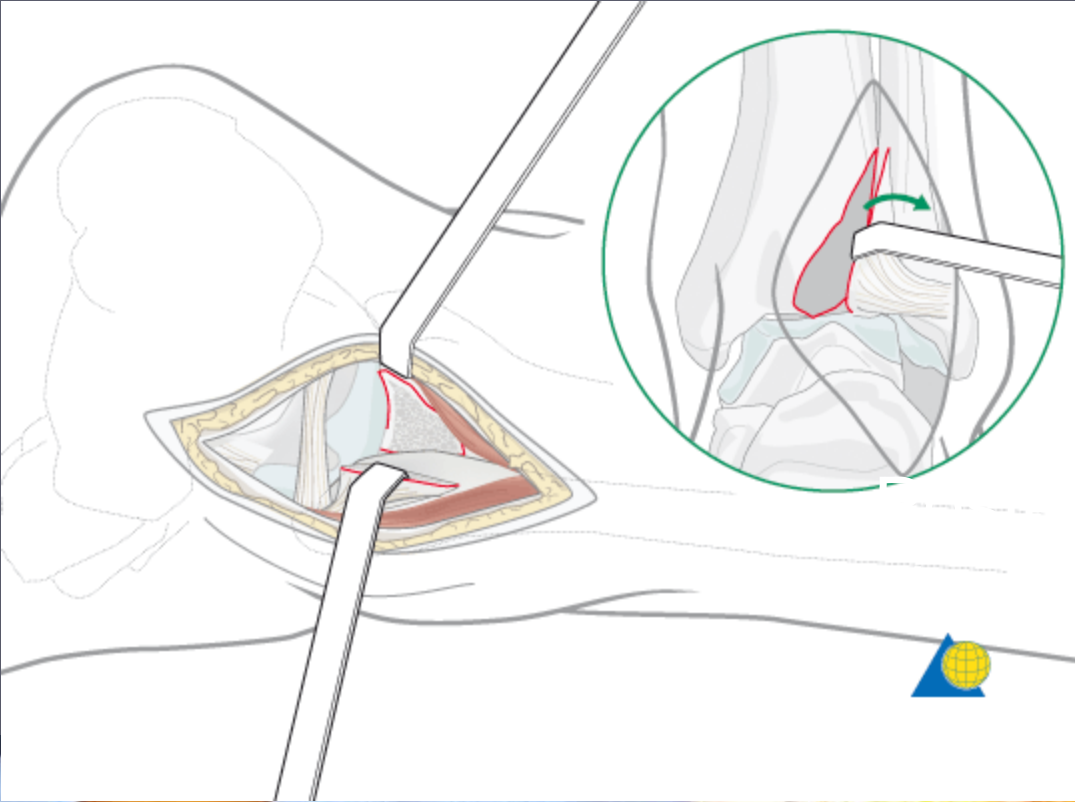


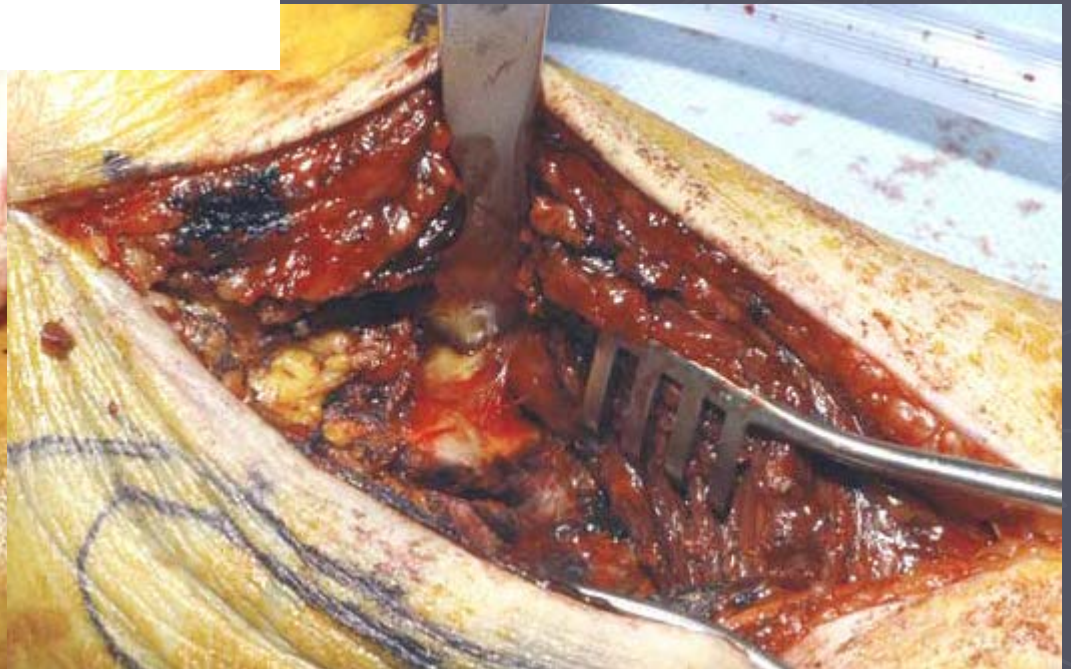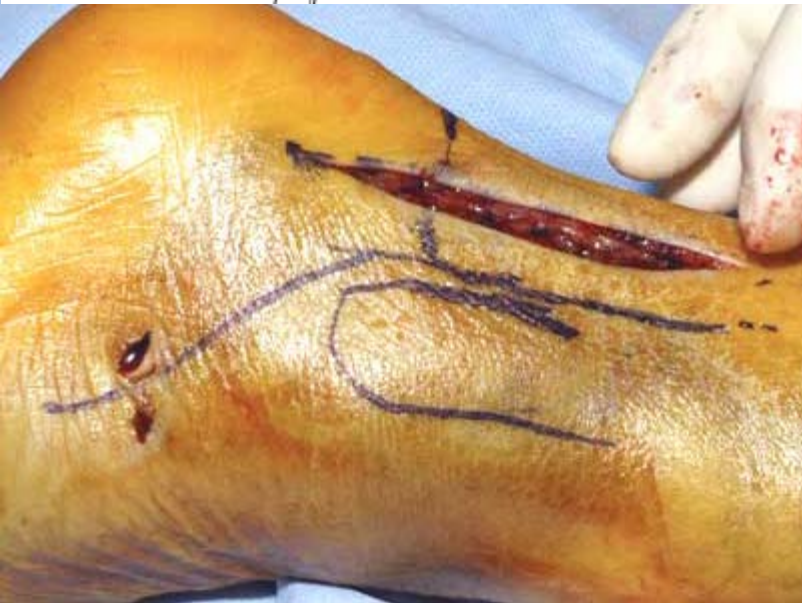60 year healthy woman, transsyndesmotic fracture AO 44-B3.2







Medial approach  
Good view and access



**Posterolateral approach (one) to both tibia and fibula**  
**Buttress plating, absolute stability**  
**Small fragment T-plate and distal posterior fibula plate**

