

Forfoden

Frank Linde

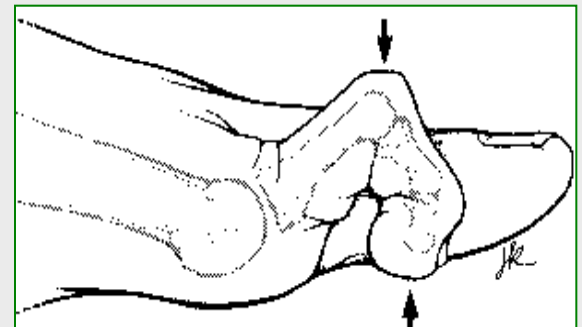
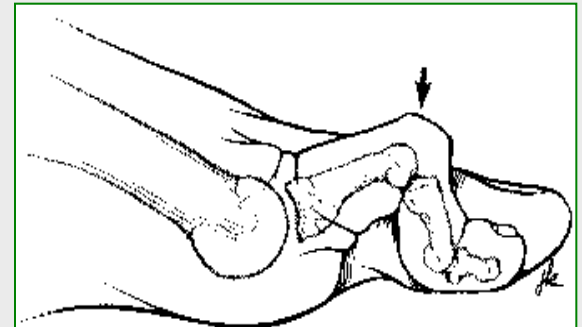
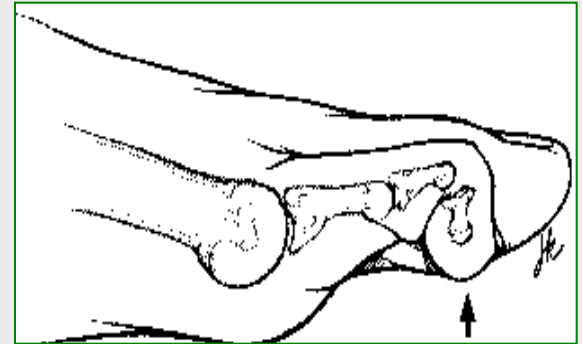
Fod/ankel-sektoren
Aarhus Universitetshospital

Forfoden

- Hallux valgus
- Hallux varus
- Hallux rigidus
- Sesamknoglesygdom
- Lilletåknyst
- Hammertæer
- Overliggende tæer
- Krølletå
- Ustabile grundled
- Monoarthritis
- Polyarthritis
- Morbus Freiberg
- Metatarsalgi
- Mortons neurom

Hammertæer

- Hammertå (mallet toe)
- Hammertå (hammer toe)
- Klotå (claw toe)

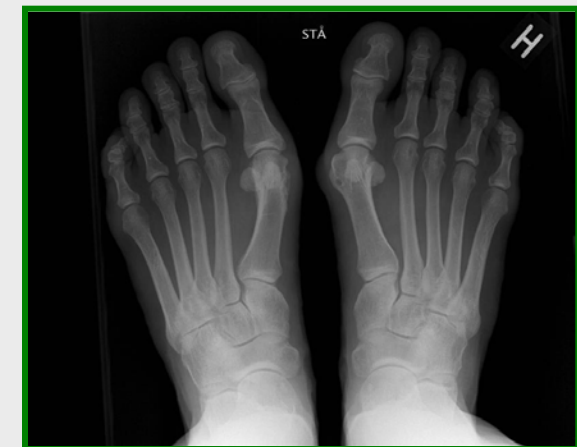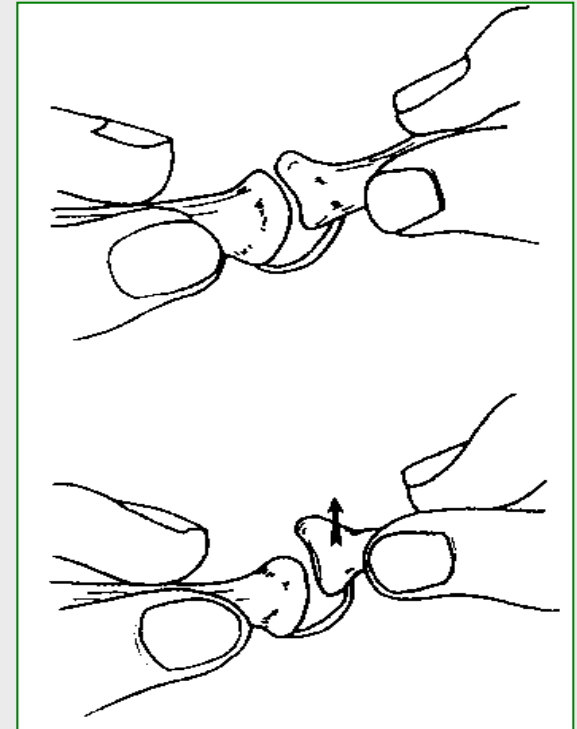


Symptomer

- Smerter, hårdhudsdannelse, sår
 - Dorsalsiden af PIP-leddet (hammertoe, claw toe)
 - Tåspidsen (mallet toe, claw toe)
- Metatarsalgi

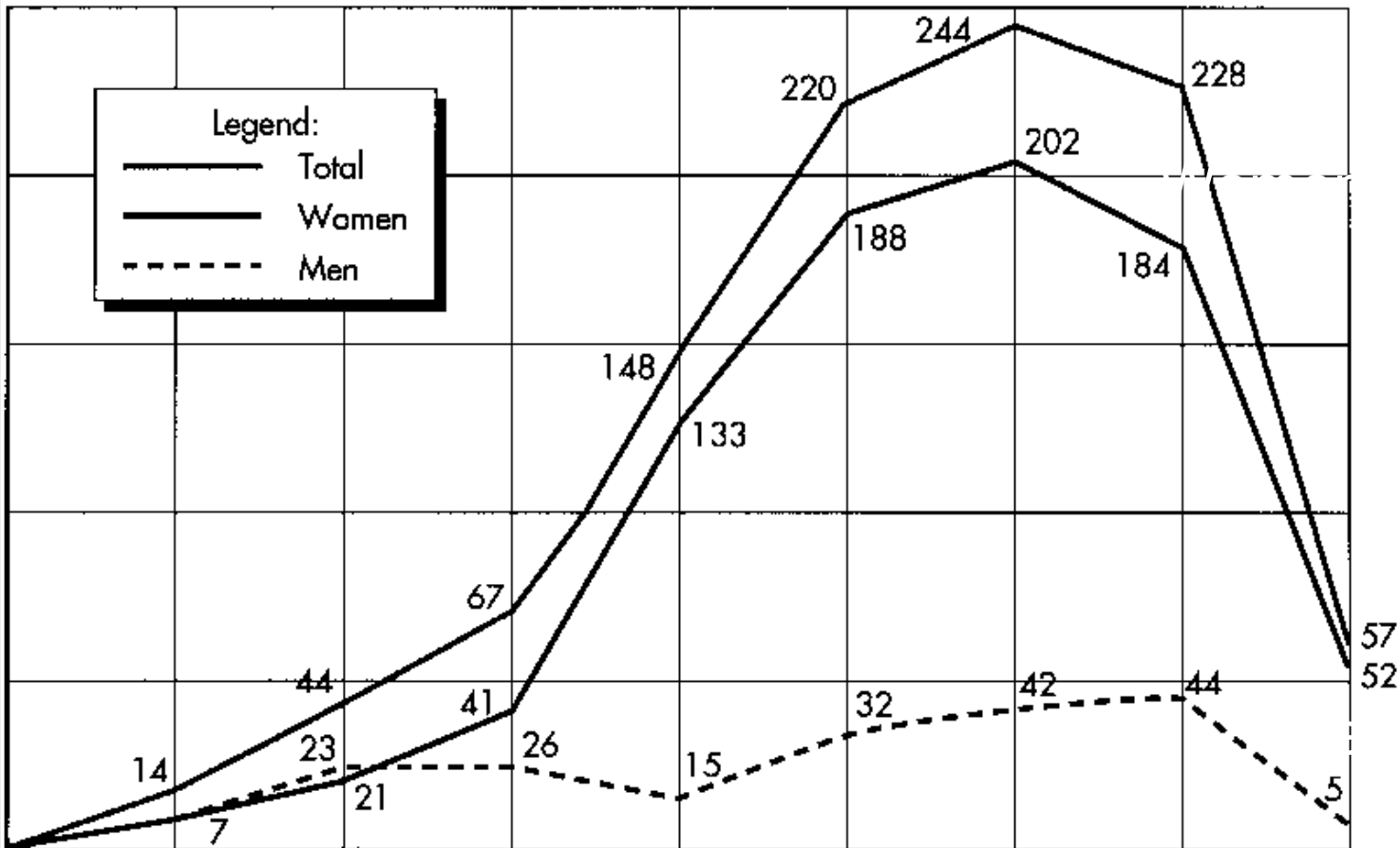
Udredning

- Hvilken hammertå type
- Fleksibel eller kontrakt
- Grundledet
 - Skuffestabilt
- Positionen af de øvrige tæer
- Positionen under belastning
- Tilgrundliggende sygdom
- Kredsløb og følesans
- Røntgen
(luksation/subluksation i grundledet)



Alders- og køns-variation

Patienter opereret for hammertæer

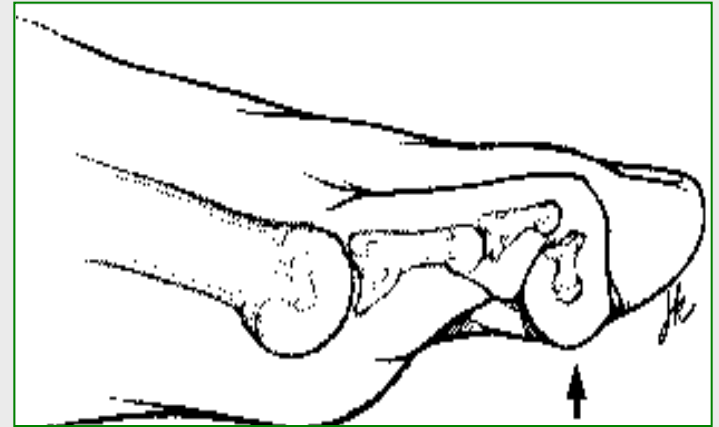


Fra Coughlin and Thompson: *AAOS Instructional Course lecture 44, 1995*

Konservativ behandling

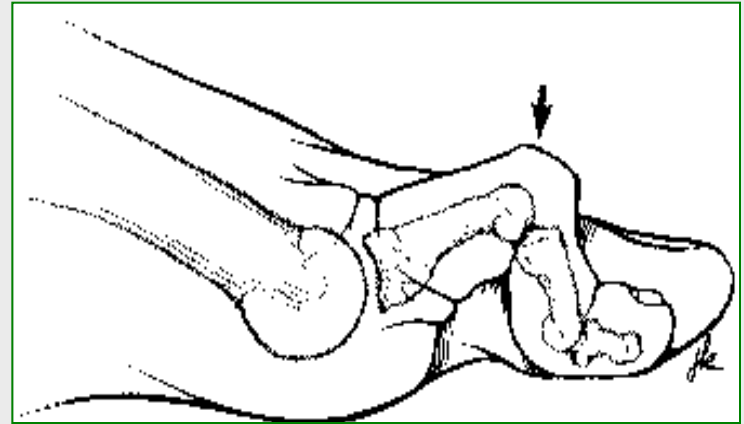
- Fodtøj med
 - Rummelig tåboks
 - Blødt overlæder
- (Forfodspelte)
- Fodterapi

Kirurgisk behandling Mallet toe



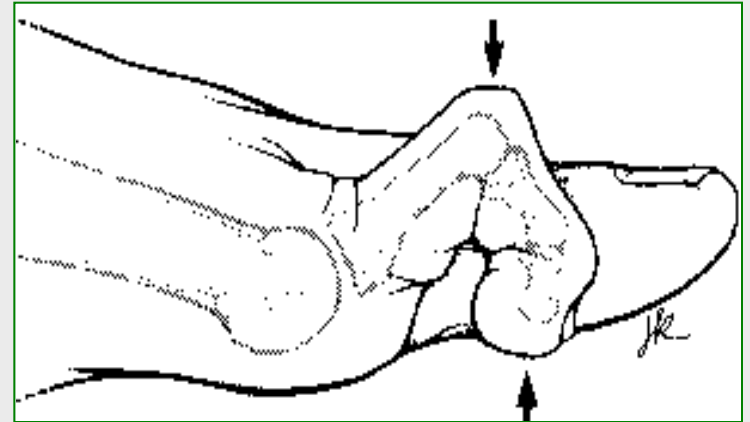
- Dynamisk
 - Percutan fleksorsene-tenotomi
- Kontrakt
 - DIP-dese
 - Fleksorsene-tenotomi
- Obs grundledet !!!

Kirurgisk behandling Hammer toe



- Dynamisk
 - Fleksor til extensor transposition
 - Eller som ved kontrakt deformitet
- Kontrakt
 - PIP-dese/condylectomi
- Obs grundledet !!!

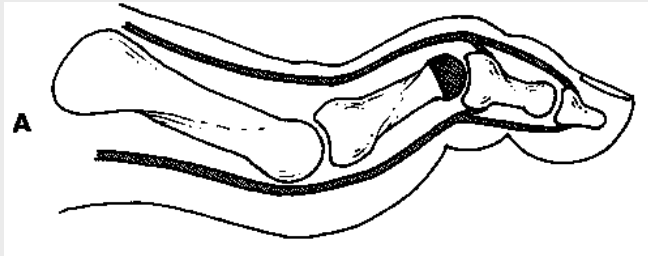
Kirurgisk behandling Claw toe



- Dynamisk
 - Fleksor til extensor transposition
- Kontrakt
 - Fleksor til extensor transposition
 - PIP-dese/Condylectomi
- Obs grundledet !!!

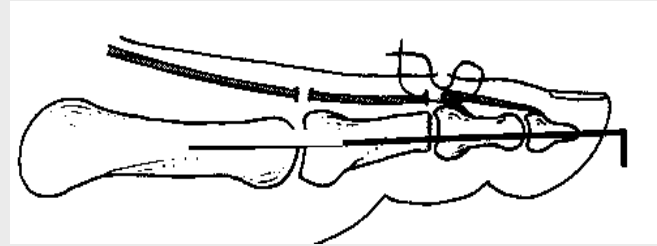
Condylectomi versus artrodese

Condylectomi



- Fordele
 - Let
 - Mere naturlig position
- Ulempe
 - Recidiv
 - Hævelse

Artrodese

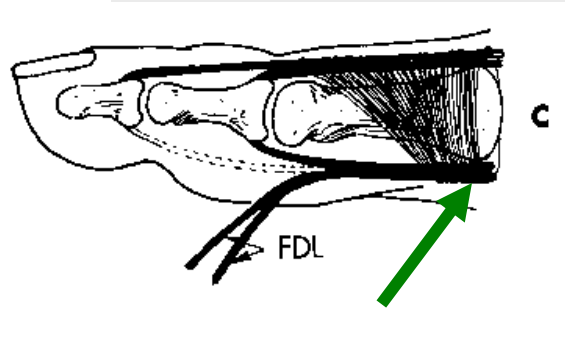
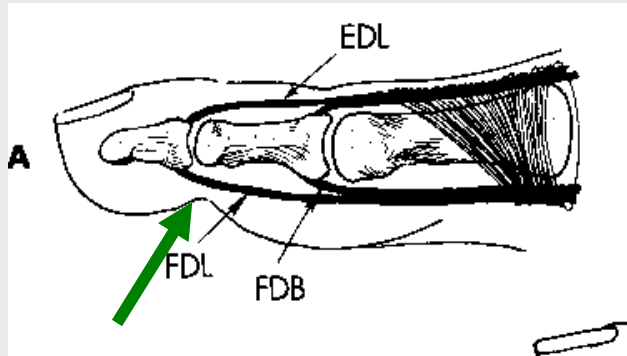


- Fordele
 - Kontrol over position
- Ulemper
 - For lige tå
 - Non-union

Flexor til extensor transposition

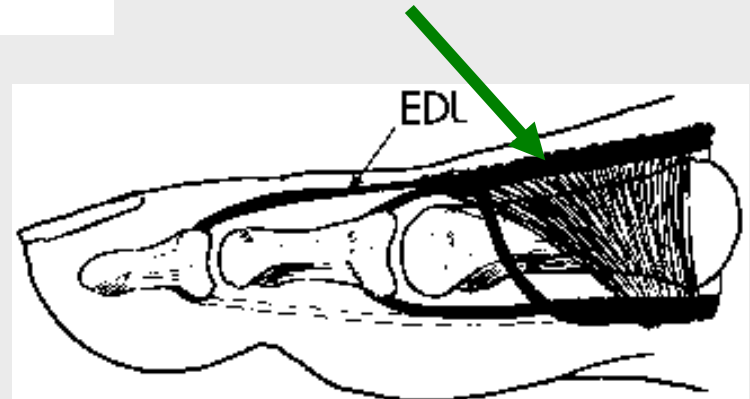
Dynamisk hammertå-operation

Percutan tenotomi lange fleksosene



Længdegående deling af lange fleksorsene

Flexor til extensor sammenfletning

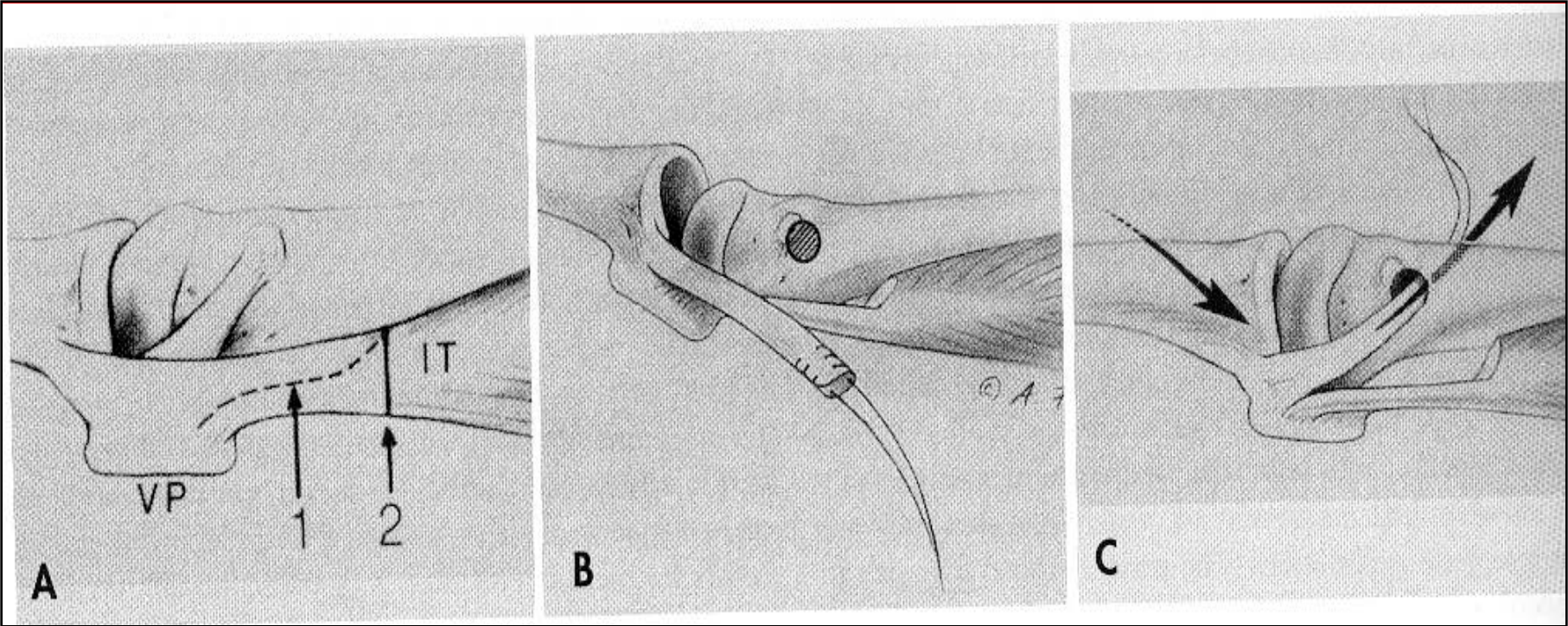


Grundledet

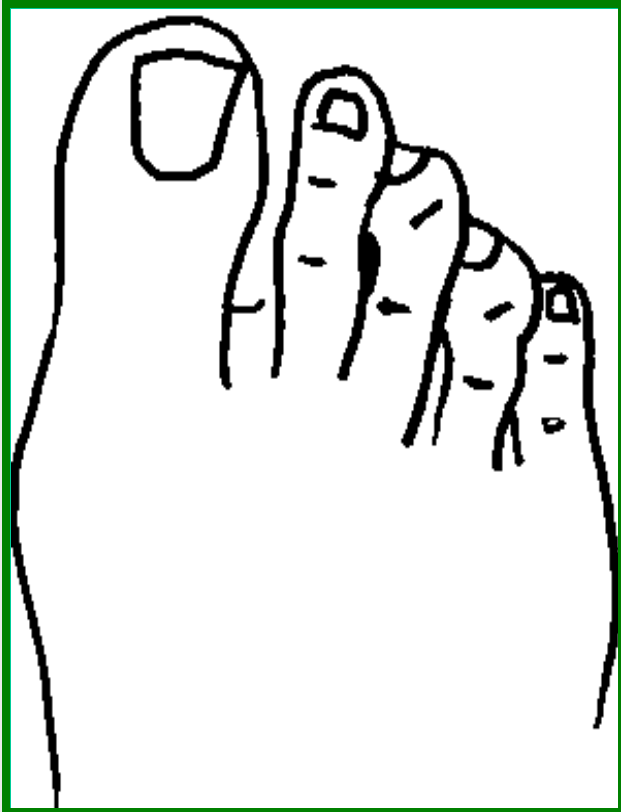
Hyperekstension, instabilitet, luksation

- Ekstensorseneforlængelse + capsulotomi
- *Hvis utilstrækkelig*
 - Flexor til extensor transposition
 - og/eller metatarsal forkortningsosteotomi
- *Ved medial/lateral deviation*
 - Balancering (Weil osteotomi)
 - Ligament-rekonstruktion (statisk el. dynamisk)

MTP-ligament rekonstruktion



Curly toe (krølletå)



Medfødt deformitet ("hypertoni"
lange fleksorsene)

Oftest 3. og/eller 4. og/eller 5. tå

Behandling:

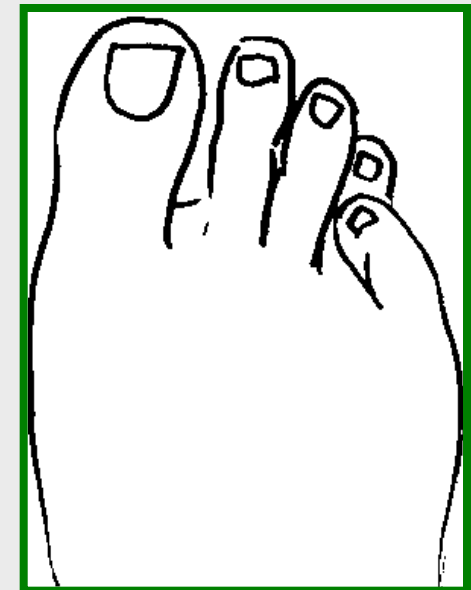
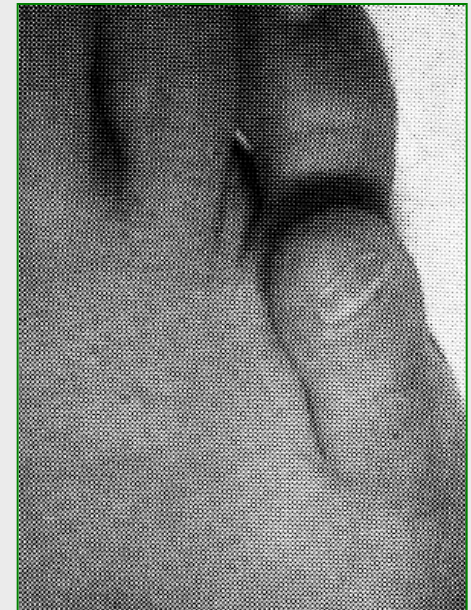Percutan fleksor-tenotomi

Mellempalanx eller yderleds
kileresection

Overliggende 5. tå

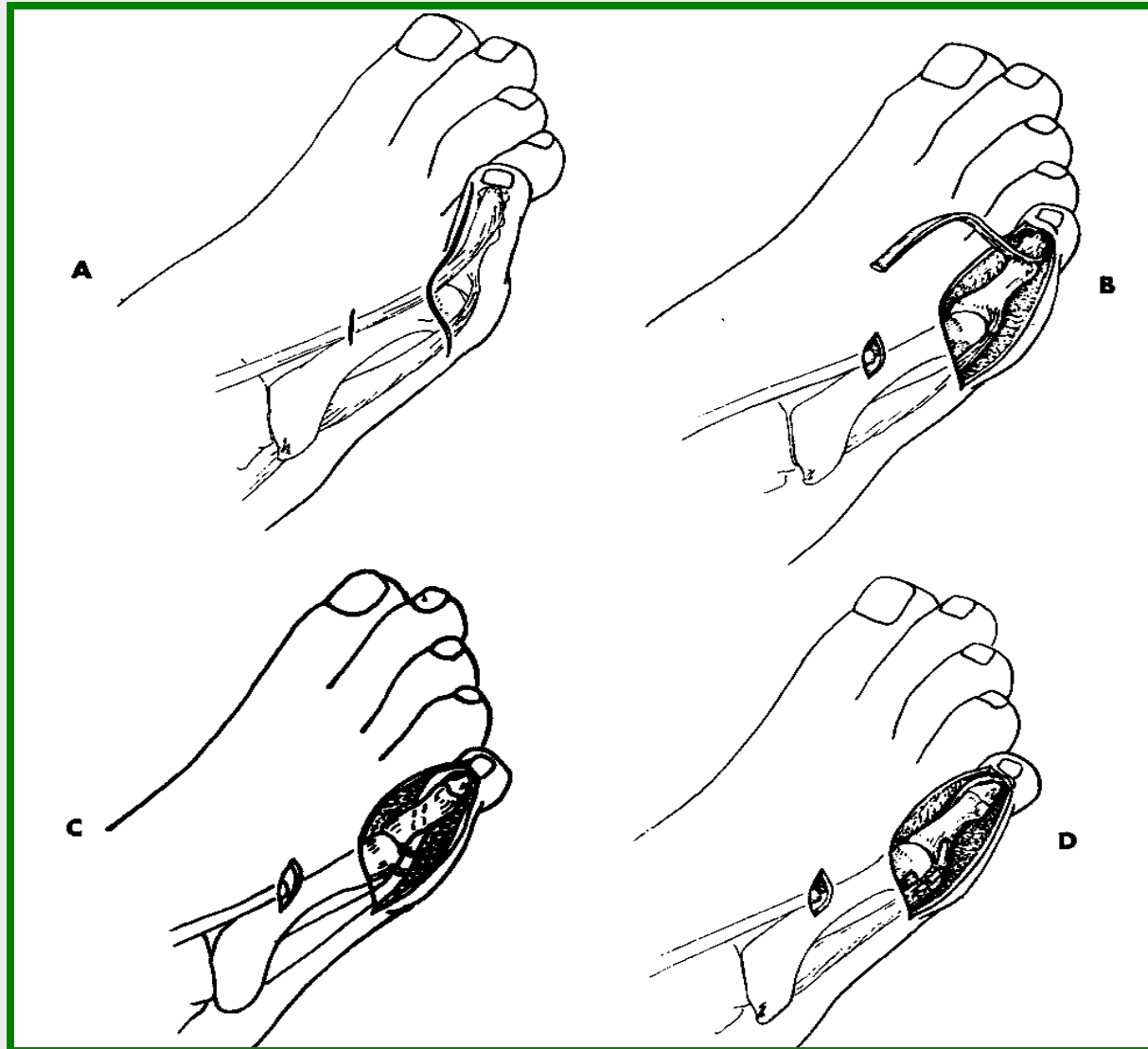
Behandling

- Ekstensorsene tenotomi
- Capsulotomi
- Hudplastik
 - DuVries
 - V-->Y plastik (Wilson)
 - Circumferential (Butler)
- Extensor sene til abductor transposition (Lapidus)



Overliggende 5. tå


Lapidus
technique



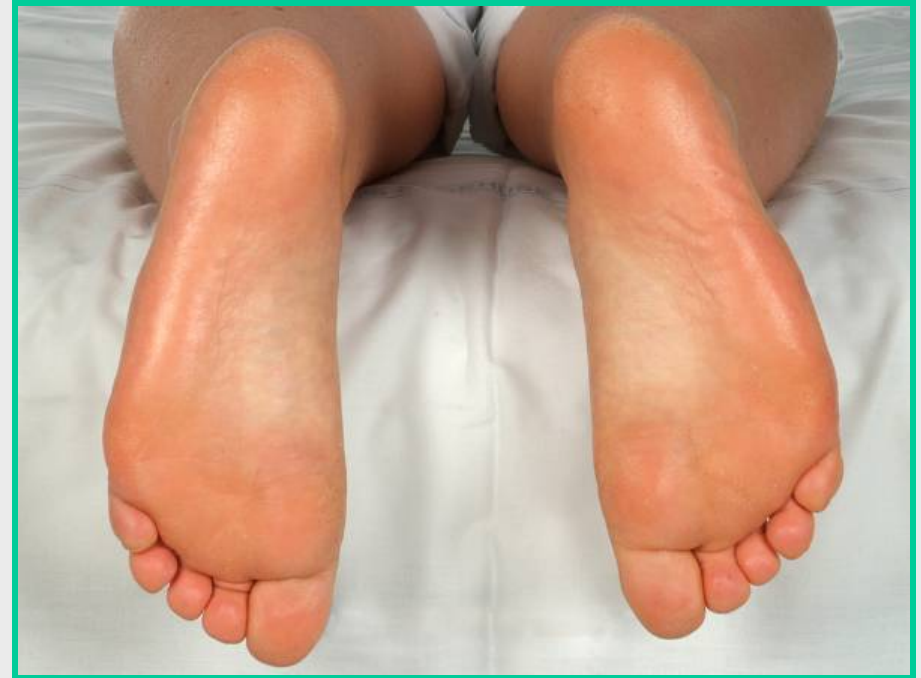Metatarsalgi forfodsnedsvækning, forfodsfald

- Smerter og
hårdhudsdannelse
under caput på
metatarserne

Fodsåleens belastning

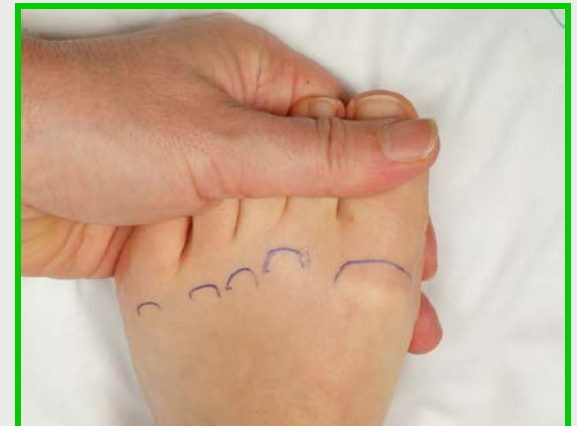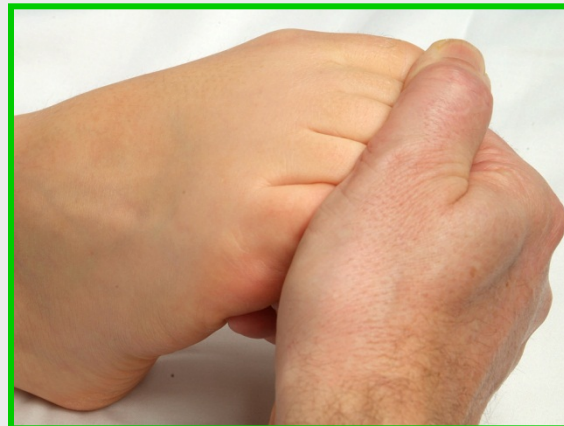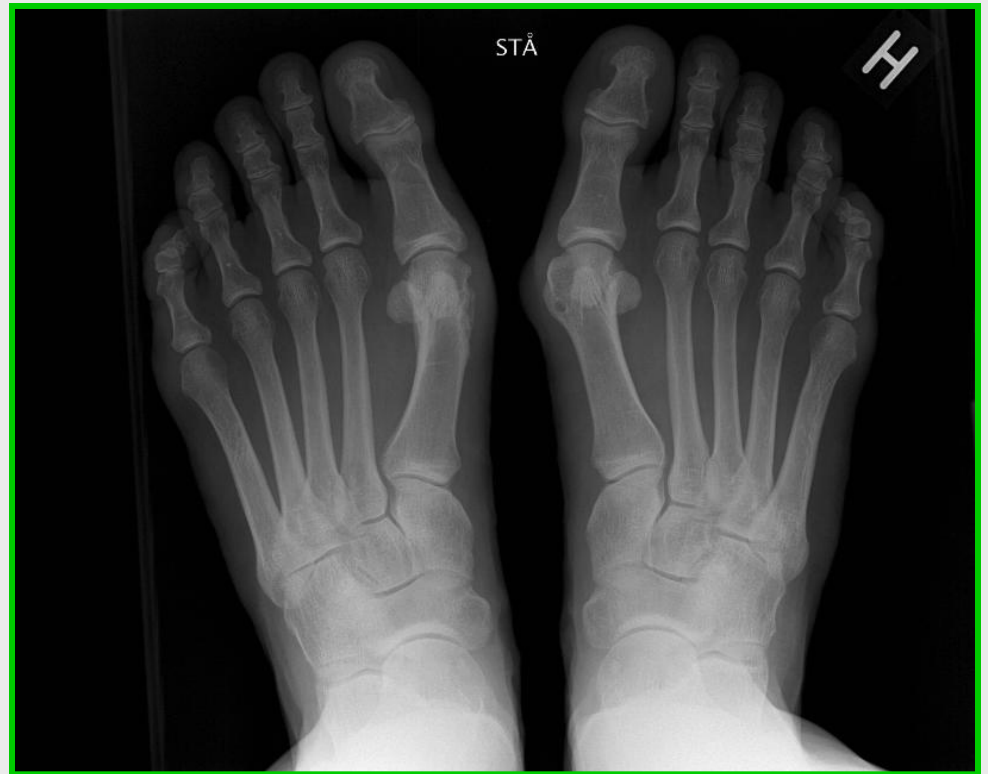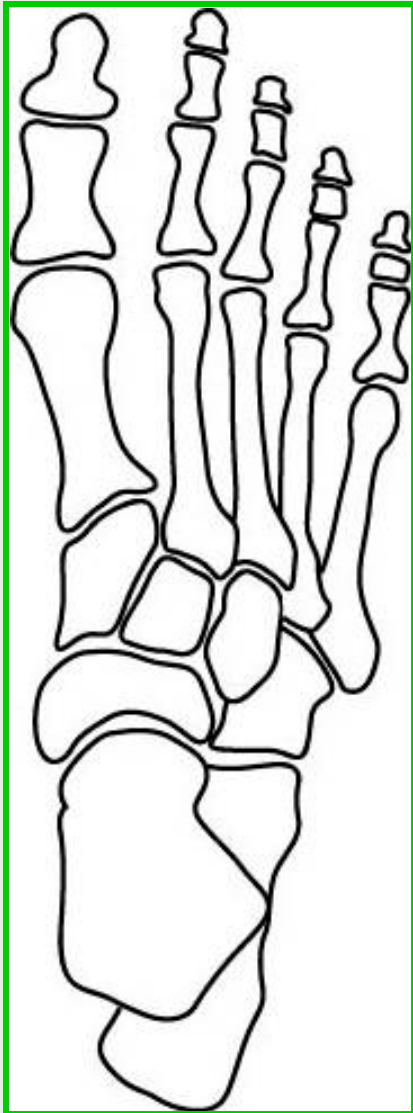


Pedografi
Ganganalyse



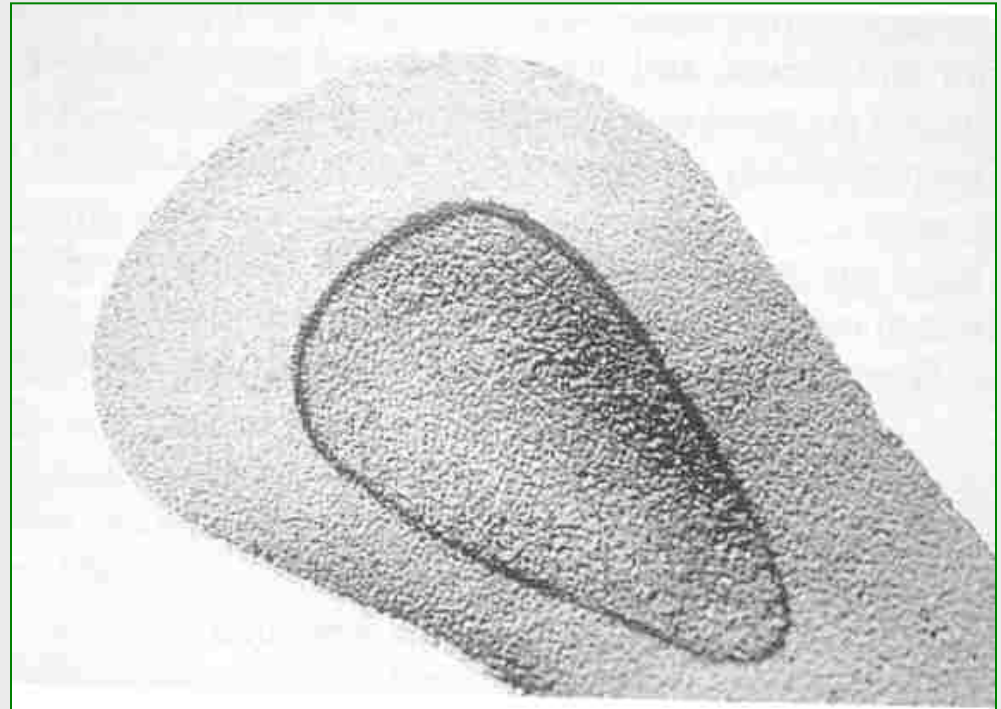
Se på placeringen af
hårhudsannelsen

Forfoden



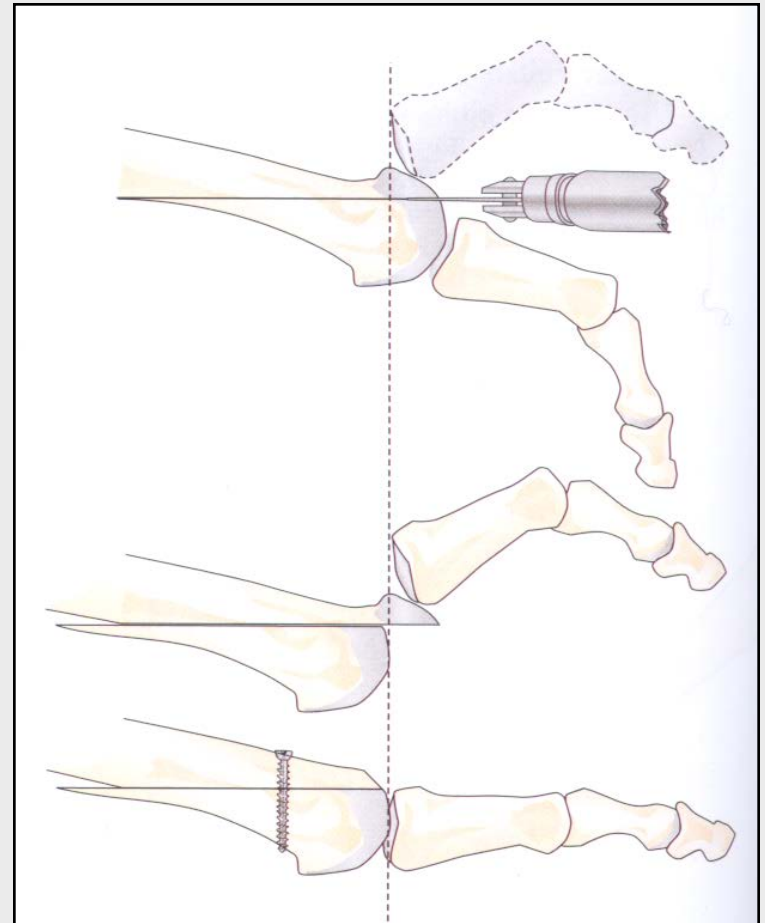
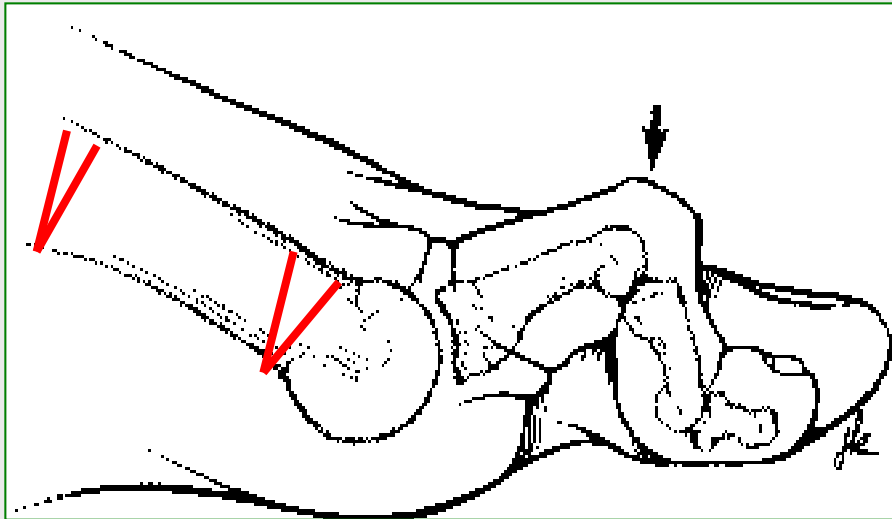
Behandling konservativ

- Forfodspelotte



Behandling kirurgisk

- Ostotomi

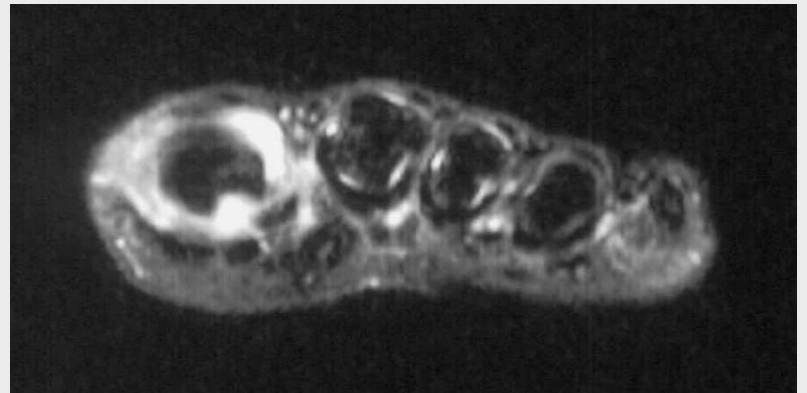
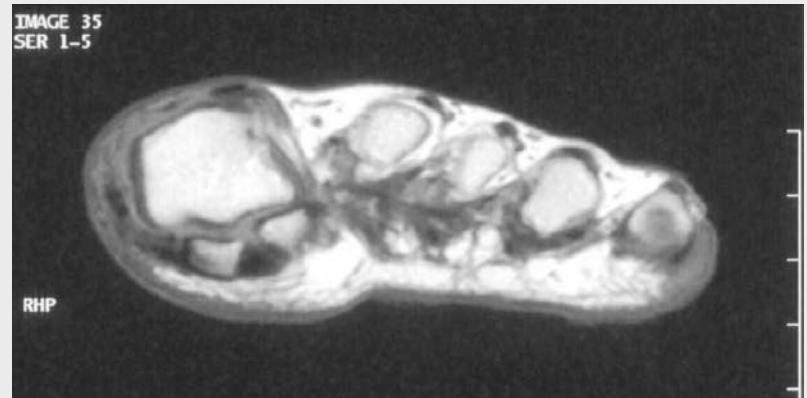


Behandling kirurgisk

- Komplikationer
 - Overførselmetatarsalgi
 - Manglende knogleheling (især de diafysære osteotomier)
 - Stivhed i grundledet (især de intraartikulære osteotomier)

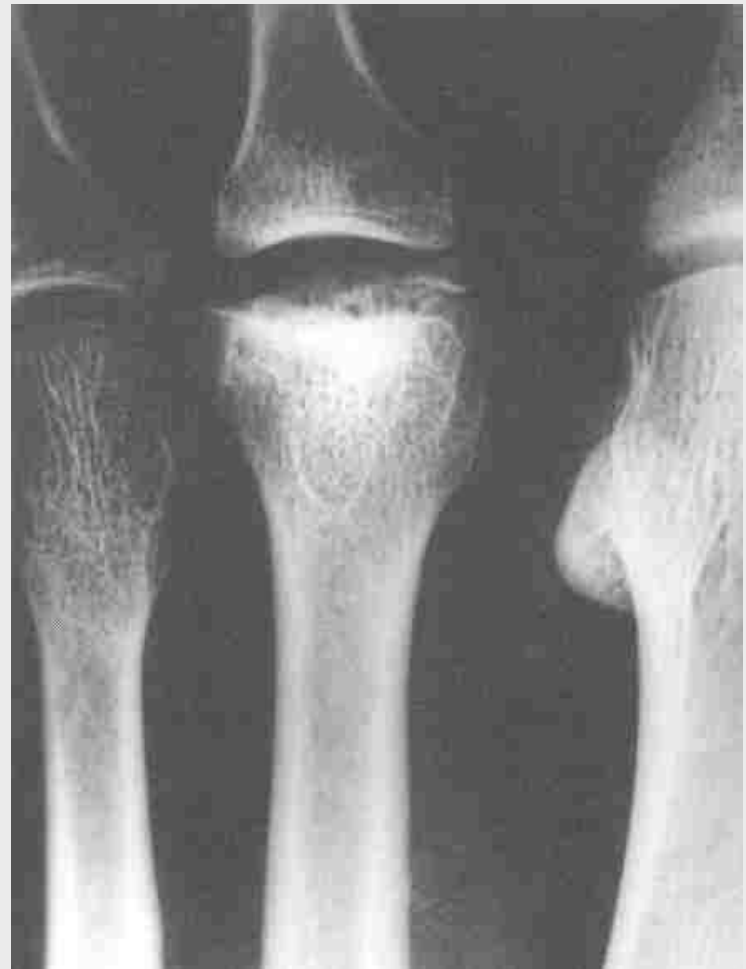Synovitis

- Differentialdiagnose ved forfodssmerter



Mb Freiberg

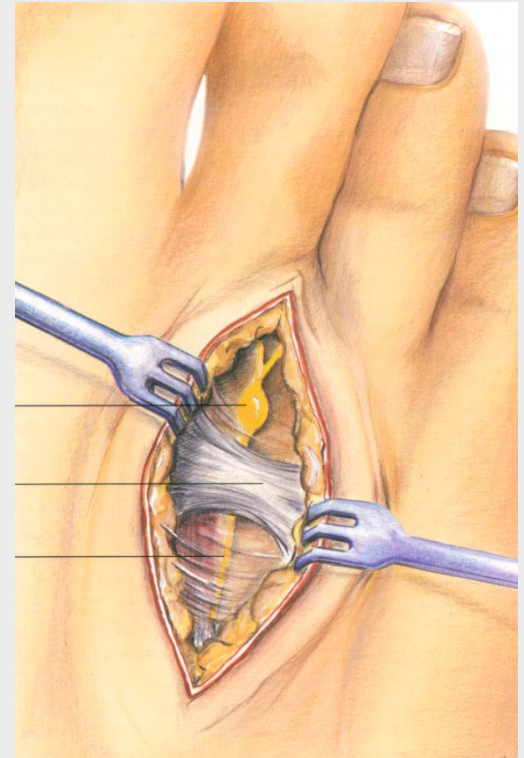
- Symptomer
 - Smerter, hævelse, senere kronisk fortykkelse, hårdhudsdannelse, metatarsalgi
- Behandling
 - Konservativ
 - Evt. operation ved kroniske tilstande



Mortons neurom

Symptomer

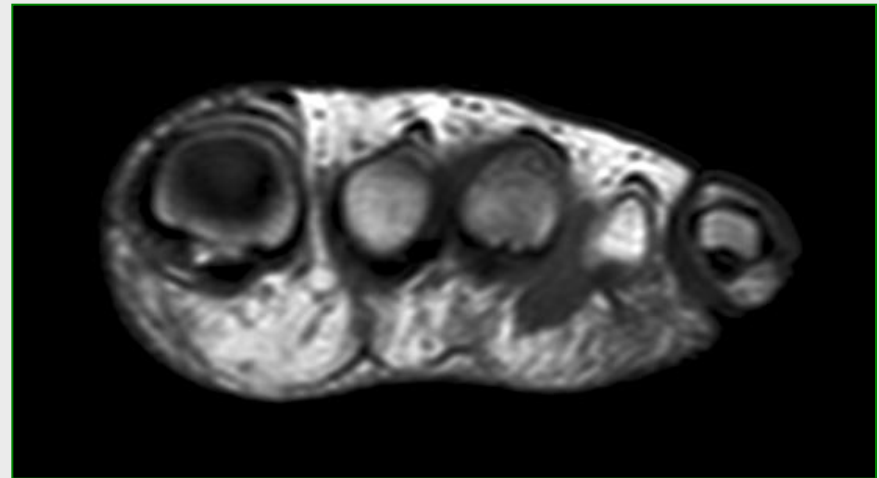
- Forfodssmerter
- Udstråling/jag mod tæerne
- Føleændringer
- Natlige smerter



Mortons neurom

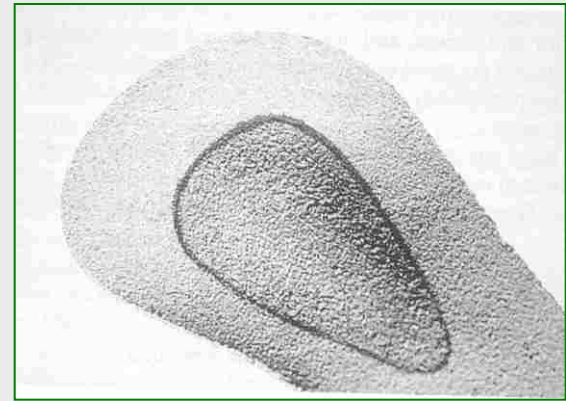
Klinik

- Ømhed ved palpation/kompression i interstitis
 - Smertejag ved mobilisering
 - Evt. føleændring på tæer
 - Lindring ved blokade
- Diagnose kan verificeres med
 - Ultralydsus.
 - MR
 - Neurofysiologisk us.



Behandling konservativ

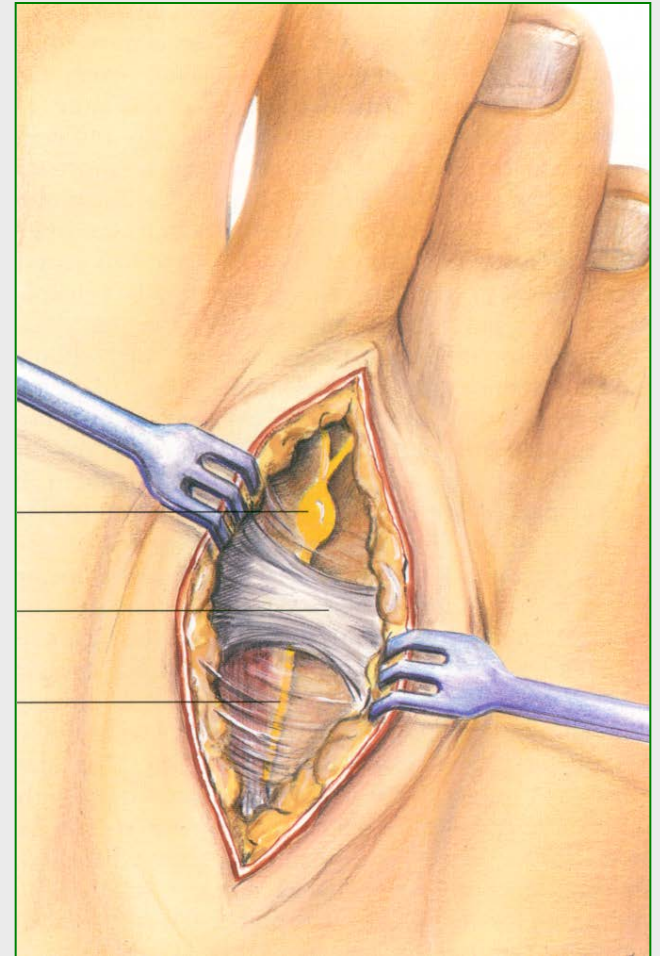
- Forfodspelotte



- Steroidinjektion

Behandling operation

- Dekompression
- Resection
 - Fra dorsalsiden
 - Fra plantarsiden



Komplikationer

- Manglende lindring
- Recidiv
- Hudatrofi (steroid)
- (Føleudfald)



Tak